

## REPORT

### VETERINARY MANAGEMENT OF MARINE OTTERS (*Lontra felina*) IN ECOLOGICAL STUDIES IN CHILE

Claudio SOTO-AZAT<sup>1</sup>, Francisca BOHER<sup>2</sup>, Gabriela FLORES<sup>2</sup>, René MONSALVE<sup>1</sup>, Alexis SANTIBÁÑEZ<sup>3</sup>, Juliana VIANNA<sup>4</sup>, Gonzalo MEDINA-VOGEL<sup>1</sup>

<sup>1</sup>School of Veterinary Medicine, Faculty of Ecology and Natural Resources, Universidad Andres Bello, República 252, Santiago, Chile, e-mail: csoto@unab.cl

<sup>2</sup>Department of Ecology, Faculty of Biological Sciences, Pontificia Universidad Católica de Chile, Alameda 340, Santiago, Chile

<sup>3</sup>Department of Aquiculture and Aquatic Resources, Universidad de los Lagos, Avenida Fuchslocher 1305, Osorno, Chile

<sup>4</sup>Department of Ecosystem and Environment, Pontificia Universidad Católica de Chile. Vicuña Mackenna 4860, Macul, Santiago, Chile

(Received 23<sup>rd</sup> March 2011, accepted 6<sup>th</sup> December 2011)

**Abstract:** The marine otter (*Lontra felina*) is a poorly studied South American otter of conservation concern. Between 2004 and 2006 as part of radiotelemetry, genetic and veterinary studies, 16 marine otters (10 males and six females), with an average body mass of  $3.8 \pm 0.3$  kg, were trapped in the coast of Central and South Chile. Twenty anaesthetic procedures were evaluated, including chemical immobilizations and anaesthesia for surgical radiotransmitter implantations. We used an intramuscular anaesthetic combination of ketamine 5 mg/kg and medetomidine 50 µg/kg. Minor complications included mild hypothermia and hypoxemia. After  $47 \pm 10$  min, anaesthesia was antagonized with atipamezole  $236 \pm 38$  µg/kg i.m. Full anaesthetic recovery was achieved at  $12.0 \pm 6.2$  min. Six otters (three males and three females) were subjected to surgical radiotransmitter placement through a ventral midline celiotomy. These individuals were housed in a quarantine room in wire-mesh cages (0.9 m long × 0.4 m wide × 0.48 m high), joined with a polyvinyl chloride pipe that served as den (1 m long × 0.4 m diameter). While in captivity, diet consisted on fresh silverside fish (*Odontesthes regia*) plus several local crab and fish species. During their acclimation period prior to surgery, these individuals received a captivity protocol which included the administration of enrofloxacin, ketoprofen, ivermectin and vitamin supplements. Three otters died in captivity, and severe and moderate ulcerative gastritis was diagnosed at the post-mortem examination. None of the operated otters had surgical complications, and full wound healing was completed by  $13 \pm 3$  days, time when the animals were released. During monitoring by radiotelemetry otters became established in their home ranges.

Keywords: Anaesthesia, captivity, chemical immobilization, ketamine, medetomidine

## INTRODUCTION

The marine otter or chungungo (*Lontra felina*) is the smallest marine mammal, and currently is listed as endangered by the World Conservation Union (IUCN, 2011, Red List of Threatened Species, <http://www.redlist.org>) (Alvarez and Medina-Vogel, 2008). This mustelid is patchy distributed along the Pacific coast of Chile and Peru (Larivière 1998; Medina-Vogel et al., 2004). Currently, research on different aspects of the biology and ecology of the species such as morphology, physiology, nutrition, reproduction, spacing behaviour, use of dens, genetics, and disease ecology is being undertaken in order to increase the knowledge of this poorly studied otter (Medina-Vogel et al., 2004, 2006, 2007). However, whenever capture, sampling, anaesthesia,

captivity and surgery of wildlife is involved, veterinary clinical management protocols should be clearly defined, in order to decrease the risks of mortality, specially when threatened species are managed (Kreeger et al., 1998; Kollias, 1999; Spelman, 1999; Soto-Azat et al., 2006).

The use of soft catch leg-hold traps have been established to be the most effective and less harmful method to trap otters (Blundell et al., 1999). Since otters are aggressive, have a strong bite, and are highly stressable carnivores, the use chemical immobilization is needed in order to reach an adequate management (Spelman, 1999). Ketamine-medetomidine, antagonized with atipamezole, is an outstanding anaesthetic protocol which presents several properties such as rapid induction, efficiency, complete antagonism and less presentation of adverse side effects than other anaesthetic combinations (Maze and Tranquilli, 1991). This makes it ideal to be used in field anaesthesia of wildlife carnivores (Jalanka and Roeken, 1990; Spelman et al., 1993; Kreeger et al., 1998; Dzialak et al., 2001; Fournier-Chambrillon et al., 2003; Miller et al., 2003). Nevertheless, secondary adverse effects as bradycardia, hypotension, hypoxemia and hypothermia may occur (Lewis, 1991; Spelman et al., 1994; Spelman, 1999; Fernandez-Moran et al., 2001).

Short term captivity in otters could be needed when reintroduction, rehabilitation, as well as application of internal radiotransmitters are required (Hoover, 1984; Hoover et al., 1984, 1985; Arnemo, 1991; Serfass et al., 1993b, 1996, Kollias 1999, Hernandez-Divers et al., 2001). In these occasions a safe and short captivity period, with the use of quarantine facilities in order to prevent any contact of captive animals and other species and their pathogens, in addition with the administration of a preventive treatment protocol and supplementation of dietary components, are advised (Kollias, 1999).

Since marine otters do not present sexual dimorphism or physical characteristic that allow to identify individuals, radiotelemetry is an excellent tool for the identification and tracking of individuals (Serfass et al., 1993b). Several methods to attach transmitters to otters have been described, these included the use of radio-collars, radio-harnesses, implanted into the subcutaneous tissue and fixed to a rear ankle or through a hind flipper (Garshelis and Siniff, 1983; Melquist and Hornocker, 1983; Mitchell-Jones et al., 1984; Ruiz-Olmo et al., 1991). However, because otters are very flexible and possess a neck wider than the head, transmitters can be removed by themselves and therefore affect the animal normal behaviour and cause significant injuries (Kruuk, 2006). This make the intra-abdominal implantation technique the best methodology to radio-track otters (Hernandez-Divers et al., 2001).

The objective of the present study was to describe the veterinary management protocols used in marine otters trapped in Chile from 2004 to 2006. Specifically the objectives were: 1) to evaluate the safety and effectiveness of “#1.5 Victor” soft catch traps to trap marine otters; 2) to evaluate the overall quality of anaesthesia and recovery produced by ketamine-medetomidine-atipamezole in this species, and to document any adverse side effects; 3) to establish a protocol for short term captivity of marine otters; and 4) to describe the surgery for intra-abdominal radiotransmitter placement in marine otters under field conditions.

## **ANIMALS, MATERIAL AND METHODS**

### **Trapping**

Between May 2004 to April 2006, 16 marine otters (10 males and six females), with a body mass of  $3.8 \pm 0.3$  kg, were captured in two locations: 1) Quintay ( $33^{\circ}11'37.4''S$ ,  $71^{\circ}41'58.1''W$ ), V Region, Central Coast of Chile (nine individuals); and 2) Colcura

(37°07'23.0''S, 73°09'56.8''W), VIII Region, South Coast of Chile (seven individuals); as part of radiotelemetry, genetic and veterinary studies. For this purpose #1.5 leg-hold traps (Victor Soft catch, Woodstream Corp., Lititz, Pennsylvania, USA) were set out of the water, above at least 15 cm of the highest tide level, anchored to rocks using steel cables and checked every 6 hr. Once an animal was trapped, it was physically restrained as quickly as possible using a blanket and leather gloves for anaesthetic administration by hand syringe (Fig. 1). Afterwards, a complete clinical examination was performed on each individual, with special emphasis of possible trap-related injuries, and its treatment. Morphometrics, blood sampling for haematology and genetics, and faecal sampling for parasitology were carried out.

### **Anaesthesia**

At the moment of capture and as induction for the surgical radiotransmitter implantation, otters were anesthetized with a combination of ketamine  $5.4 \pm 0.8$  mg/kg (Ketostop, Drag-pharma Invetec S.A., Santiago, Chile), and medetomidine  $54 \pm 8$  µg/kg (Domtor, Pfizer, Madrid, Spain), administered deeply into the semitendinosus, semimembranosus or *longissimus dorsi* muscles, by hand syringe. Actual weights were generally lower than the estimated weights used to calculate drug dose; as a result, the actual dosages of ketamine–medetomidine were slightly higher than intended (ketamine, 5.0 mg/kg and medetomidine, 50 µg/kg). During anaesthesia initial effect time, induction period and reversal time were recorded. In addition, a complete monitoring of the cardiac rate, respiratory rate, rectal temperature, capillary refill time, relative percent oxyhemoglobin saturation (SpO<sub>2</sub>), mean arterial blood pressure, anaesthetic depth and degree of analgesia, were recorded at 5-min intervals, from 5 to 30 min, and again at 40 min, post-injection of the anaesthetic combination. Once the procedures were completed, atipamezole  $236 \pm 38$  µg/kg i.m. was administered at  $47 \pm 10$  min of the initial ketamine-medetomidine administration. Animals were recovered in holding or transport cages covered with a sheet to create a warmed and darkened environment, to facilitate a smooth recovery. A total of 20 anaesthetic events were evaluated.

### **Captivity**

The nine otters captured in 2004 in Quintay, were immediately transported to a quarantine room at the Marine Research Centre of the Universidad Andres Bello, and were individually housed in wire mesh cages (90 cm long × 40 cm wide × 48 cm high) joined to a den/transport polyvinyl chloride (PVC) pipe (100 cm long × 40 cm diameter) (Fig. 2). Diet was offered soon after arrival and consisted in daily 900 g of fresh silverside (*Odontesthes regia*), flounder (*Paralichthys microps*) and local crabs (*Homalaspis plana*, *Cancer spp.* and *Mursia gaudichaudi*). Individuals were subjected to a captivity protocol, for at least five days, which was included in the diet. This consisted in 2.5 mg/kg of enrofloxacin b.i.d. (Rostrum, Drag-pharma Invetec S.A.); 0.5 mg/kg of ketoprofen s.i.d. (Naxpet, Drag-pharma Invetec S.A.); 0.075 ml of A, D, E vitamin supplement s.i.d. (Inveade, Drag-pharma Invetec S.A.); and 2.5 ml of B vitamin complex b.i.d. (Hematon B12, Eximerk Ltda., Santiago, Chile). Also, a single dose of 200 µg/kg of ivermectin was administered subcutaneously (Crack, Laboratorio Chile S.A., Santiago, Chile). The individuals underwent an acclimation period for two weeks, time where otters showed activities such as grooming, scent-marking and good acceptance of food, and therefore they were judged to be in good health to be subjected to the surgery.

### **Surgical intra-abdominal radiotrigger placement**

Six otters (three males and three females) were subjected to the surgical intra-abdominal radiotrigger implantation. Otters were fasted for 6 hr and water was withdrawn 3 hr before the beginning of the surgical procedure. Anaesthetic induction was achieved with the administration of ketamine and medetomidine in the same manner described for the capture. An area of 6 × 4 cm of the ventral midline, cranial to the umbilicus, was shaved first with electric clippers and then with a scalpel blade, followed by a scrub with chlorhexidine 0.5%. Isoflurane 2.7 ± 0.8% (Isoflurano USP 100%, Baxter, Guayama, Puerto Rico, USA) and oxygen 2 l/min were administered for anesthetic maintenance via face mask. A 4 cm craniocaudal incision was made in the centre of the prepared area using a N° 20 scalpel blade. The muscle layer was exposed by blunt dissection, and 3.5 cm of muscle and peritoneum were then transected through the *linea alba*. Thus the radiotrigger was inserted into the abdominal cavity. The six transmitters used (VHF 150-151 MHz, Sirtrack Ltd, Havelock North, New Zealand) were especially designed for marine otters, in regard of its size and locomotion patterns. They were 3.5 cm long × 3.2 cm wide × 1.0 cm high and weighed of 15.3 g, equivalent to 0.4% of the otters body weight. They were disinfected in chlorhexidine 10% for 40 min and then rinsed in abundant 0.9% NaCl sterile solution before their placement. Closure of the incision was made in three layers with the use of absorbable polyglycolic acid number 2/0 (Safil, Braun, Tuttlingen, Germany). Once the surgical procedure was completed intramuscular injections of: 30,000 IU/kg of penicillin G (150,000 IU/ml, Bipencil L.A., Laboratorio Chile S.A.), 1 mg/kg of ketoprofen were administered. The surgical wound was daily examined and disinfected with abundant povidone-iodine 3% solution applied at distance with a 60 ml syringe. Otters were kept in captivity until their surgical wounds were entirely healed. Afterwards otters were released in the same places they were captured and were subsequently radio-tracked until the radiotriggers did not emit signals anymore.

## **RESULTS**

### **Trapping**

A total of 1,560 traps-days were required to trap 16 otters, completing an effort of 97.5 traps day/otter. The clinical examination performed immediately after capture, revealed moderate inflammation and minor cutaneous lacerations of the trap-exposed area in 13 individuals. Two otters captured in Colcura presented a luxation of the interphalangeal joints, which recovered well with one and three days of restricted activity in holding cages, respectively. One juvenile female marine otter captured at Quintay, suffered an open fracture of the second phalanx on the second digit of the left forelimb, caused by self-mutilation rather than directly by the trap (see Table 1). This otter was treated with 25 mg/kg flucloxacilin q.i.d. (Flucloxacilina, Mintlab Co., Santiago, Chile), 1 mg/kg ketoprofen s.i.d., and flushes of povidone-iodine 3% applied at distance twice a day. None dental injuries were observed in any of the trapped otters.

### **Anaesthesia**

Ketamine-medetomidine produced a rapid and smooth anaesthetic induction for all individuals. Mean time to initial effect and induction period were 2.2 ± 1.0 (1.1–5.0) min and 4.2 ± 2.5 (1.8–12.0) min, respectively. Anaesthetic recovery following atipamezole administration was smooth, with no evidence of seizures or re sedation; mean reversal time was 12.0 ± 6.2 (2.4–26.8) min. Anaesthesia was deep and stable in

all otters. Rectal temperature decreased for most otters during the anaesthetic period, and six marine otters captured in 2004 developed mild hypothermia ( $< 36.7^{\circ}\text{C}$ ) by the end of the procedures. For that reason external heat sources were applied to the otters trapped in 2006. Although the same tendency was observed with the 2006's otters, no hypothermia was recorded (Fig. 3a). Mean cardiac rate was  $133 \pm 19$  beats/min, and remained generally stable throughout the monitoring period (Fig. 3b). All values for capillary refill time ranged from 1–3 sec and were judged normal. Respiratory rate was  $26 \pm 13$  breaths/min, and remained stable, with a slight increase at the last 10 min of monitoring, which coincided with the anaesthetic recovery of otters (Fig. 3b). Values for  $\text{SpO}_2$  were relatively low soon after induction; however, ten minutes after anaesthetic administration, all mean values remained over 90% (Fig. 3c). Mean arterial blood pressure, measured only in four otters, was  $115 \pm 30$  (64–163) mmHg during the 30 min of monitoring (Fig. 3d).

**Table 1.** Summary of 16 marine otters (*Lontra felina*) captured in 2004 and 2006, in Central and South Chile

Date	Individual <sup>a</sup>	Body mass (kg)	Total length (cm)	Trap-related injury type <sup>b</sup>	Anaesthesia <sup>c</sup>	Observations
May 2004	QF1	3,9	86	I	Ket-Med	
May 2004	QF2	3,2	85	IV	Ket-Med	Open digit fracture
June 2004	QF3 (†)	4,2	90	I	Ket-Med	Ulcerative gastritis
June 2004	QF4	3,3	87,5	I	Ket-Med	
June 2004	QM1	3,8	86	I	Ket-Med	
June 2004	QM2	3,8	90	I	Ket-Med	
June 2004	QM3	4,1	87	I	Ket-Med	
July 2004	QM4 (†)	4,1	80	I	Ket-Med	Acute ulcerative gastritis
July 2004	QM5 (†)	4	86,5	I	Ket-Med	Acute ulcerative gastritis
April 2006	CM4	4,1	80	I	Ket-Mid	
April 2006	CM5	3,9	82,9	I	Ket-Mid	
April 2006	CM1	3,7	75	I	Ket-Med	
April 2006	CM2	4,1	80	II	Ket-Med	
April 2006	CF1	3,2	78,5	II	Ket-Med	
April 2006	CF1	3,2	78,5	I	Ket-Med	
April 2006	CM3	3,8	80	I	Ket-Med	

<sup>a</sup> Q = Quintay. C = Colcura. F = female. M = male. † = died in captivity.

<sup>b</sup> I = superficial wounds, missing claws, or inflammation; II = luxation of the interphalangeal joints; III = closed digital fracture; IV = open digital fracture. Adapted from (Fernandez-Moran et al. 2002).

<sup>c</sup> Ket = ketamine; Med = medetomidine; Mid = midazolam.

## Captivity

Otters that were subjected to short term captivity, consumed an average of  $617 \pm 93$  g/day of food. Most otters improved their body condition and an increase of  $217 \pm 301$  g in weight was recorded. From the nine otters kept in captivity in 2004, three

(two males and one female) died within three and six days after capture. One of these otters did not accept any food offered, while the others ate only partial rations. On the day of death all otters (two kept simultaneously), developed an acute, black and smelly diarrhoea. At the post-mortem examination, it was diagnosed an ulcerative gastritis, acute in the two males and moderate in the female (Table 1). *Citrobacter freundii* and *Citrobacter* sp. were possible to isolate from the gastric content of the two most affected otters.



**Figure 1.** Male marine otter (*Lontra felina*) trapped with a # 1.5 soft catch leg-hold trap in Colcura, VIII Region, Chile. Physical immobilization with the use of leather gloves is performed in order to administrate a combination of ketamine and medetomidine i.m. by hand syringe.

### **Surgical intra-abdominal radiotransmitter placement**

Surgeries lasted for  $57.5 \pm 4.5$  min and subsequently the animals were fully recovered from anaesthesia (return to an ambulatory state)  $16.6 \pm 5.7$  min after the administration of the antagonist atipamezole. The recovery was slight and neither seizures nor re-sedation were recorded. One minor surgery-related complication occurred. One otter presented swelling of the surgical site that lasted longer than the other individuals, reason why it was left in captivity two more days than the other otters before its release. Overall, the healing of the surgical incision was complete at  $13 \pm 2$  days, time when otters were released in the same places they were trapped and radio-tracked for the next  $100 \pm 30$  days. All tagged individuals emitted a clear signal picked up until a distance between 100 and 1,200 m depending on the animal's location. During this period all the tagged animals showed an apparently normal behaviour and were able to establish in their home ranges which included the area they were captured. None mortality was recorded during the post-release monitoring period.



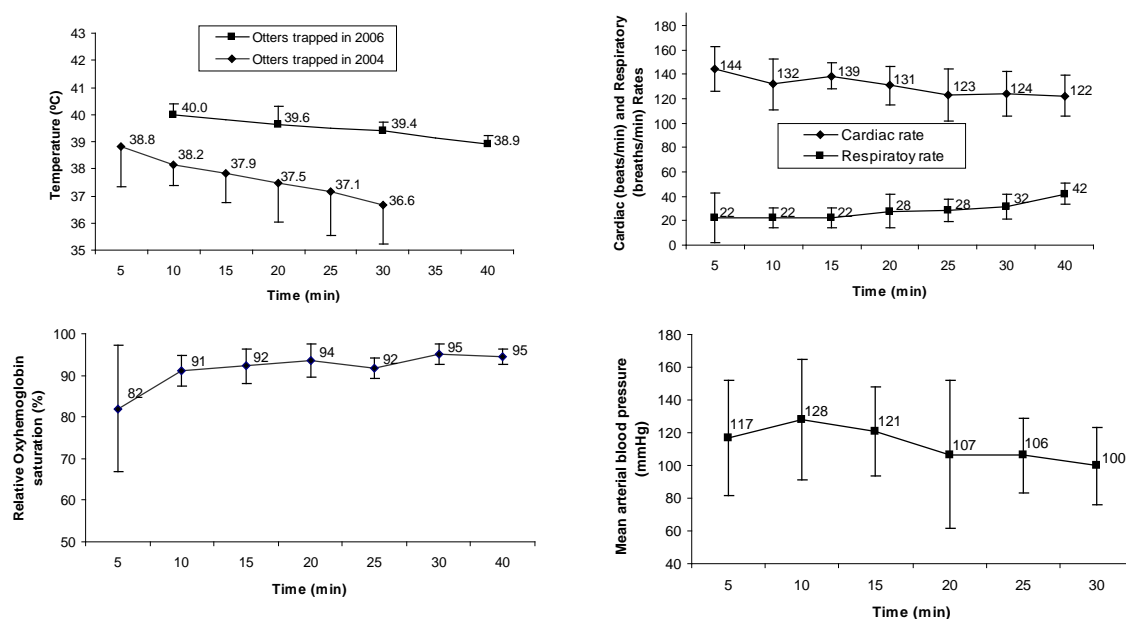
**Figure 2.** Captive marine otters (*Lontra felina*) individually housed in a quarantine room at the Quintay Marine Research Centre, Universidad Andres Bello.

## DISCUSSION

The use of soft catch traps, have been demonstrated to be safer and more effective to trap North American river otters (*Lontra canadensis*), when compared with Hancock traps (Blundell et al., 1999). Although, a good alternative for otter capture is the use of Tomahawk traps or wooden boxes (Kruuk, 2006), its bigger size does not allow its set up in the rocky seashore where marine otters normally inhabit (Medina-Vogel et al., 2007). Nevertheless, two otters presented digital luxations, and one otter suffered an open digital fracture, indirectly caused by the trap, these responded well to treatment. In addition, the subsequent tracking of the fractured otter, by telemetry evidenced an apparently normal behaviour (Medina-Vogel et al., 2007).

Because two otters showed signs only of mild sedation after initial drug administration (not included in the analysis), possibly due to subcutaneous administration of the anaesthetics, they were supplemented with half the initial dose of both ketamine and medetomidine with good effect. These events confirm the importance of a well placed, deep i.m. injection (Spelman, 1999). We recommend the use of external heat source during anaesthesia, since in the otters captured in 2006, clearly increased its temperature, subsequently none of these otters presented

hypothermia (Fig 3a). Respiratory depression at the beginning of anaesthesia is a common adverse effect presented with the use of medetomidine (Jalanka and Roeken, 1990; Spelman et al., 1994; Spelman, 1999; Fernandez-Moran et al., 2001). This was not observed in marine otters when based on the respiratory rate alone. However, in the cases measured, SpO<sub>2</sub> was initially low enough to raise concerns. Similar to reports in North American river otters and Eurasian otters (*Lutra lutra*), these values improved quickly with time and stimulation (Spelman et al., 1994). Relative oxyhemoglobin saturation should be measured whenever medetomidine is used in this species and oxygen for intubation should be on hand if needed. Although the sample size was small, arterial blood pressure changes in marine otters followed the trend expected when alpha 2-adrenoceptor agonists are used: an initial increase followed by a decrease. However, as it was used in combination with a dissociative agent, hypotension (< 50 mmHg) was not observed (Muir et al., 2001).



**Figure 3.** (a). Mean and SD for rectal temperature (otters captured in 2004,  $n = 15$ ; and otters captured in 2006,  $n = 5$ ); (b). Cardiac and respiratory rate ( $n = 20$ ); (c). Relative oxyhemoglobin saturation ( $n = 11$ ); and (d). Mean arterial blood pressure ( $n = 4$ ), for 16 different marine otters anesthetized with ketamine  $5.4 \pm 0.8$  mg/kg and medetomidine  $54 \pm 8$   $\mu$ g/kg, and monitored through 40 min.

In an attempt to test new anaesthetic protocols, two marine otters captured in Colcura in 2006, were anesthetized with a combination of ketamine 10 mg/kg and midazolam 0,25 mg/kg i.m. (these anaesthetic procedures were not included in the study). The first otter showed excessive salivation and cough, while the second developed a moderate hypoxemia. Also, both otters presented long recoveries (full recovery  $128 \pm 11$  min) with re-sedation, and “cobra” like movements during recovery was observed in one otter. Because of the side effects observed, and also since midazolam has not have an effective and full antagonist agent (Spelman, 1999), we recommend the use of ketamine and medetomidine.

Different methods to attach radiotransmitters to otters have been described. Mitchell-Jones et al. (1984) used radio-harnesses in Eurasian otters, however, they stayed few days or weeks on animals, and serious skin lesions appeared when they were tighten. Garshelis and Siniff (1983) used transmitters attached to the neck, ankle and feet of sea otters, which were rapidly removed by tagged individuals causing lacerations, digital fractures and even death of some otters. Subcutaneous implantations in sea otters and Eurasian otters have not had satisfactory results, and



suture removing with subsequently transmitter exposure and death of some individuals have been reported (Garshelis and Siniff, 1983; Ruiz-Olmo et al., 1991). It was Melquist and Hornocker (1983), shortly after their first results of radio-collared otters, that suggested and developed the use of internal transmitters. Afterwards, radio-tracking studies using intra-abdominal transmitters has been carried out in North American river otters (Erickson and McCullough, 1987; Serfass et al., 1993a), sea otters (*Enhydra lutris*) (Garshelis and Siniff, 1983), Cape clawless otters (*Aonyx capensis*) (Arden-Clarke, 1986; Somers and Nel, 2004), Smooth-coated otters (*Lutrogale perspicillata*) (Hussain and Choudhury, 1995), Eurasian otters (Sjøasen, 1997, Durbin, 1998; Fernandez-Moran, et al., 2002), spotted-necked otters (*Lutra maculicollis*) (Perrin and Carranza, 2000), and Southern river otters (*Lontra provocax*) (Soto-Azat et al., 2004, 2006). The advantages of its use include a longer permanence, functionality and no interference with the normal behaviour of implanted animals. Even though, the intra-abdominal radiotransmitter implantation was a relatively straightforward procedure, the average 58 min of surgery can be explained in part by the long time needed to prepare the surgical area due to the dense fur otters possess, but also because other activities, such as clinical examination, blood sampling and morphometric measurements were performed during the surgical procedure. Although, we did not see reproductive activity after release in the tagged animals, probably because of the short life span of the transmitter batteries, a cylindrical radiotransmitter of longer dimensions (10 cm long × 2 cm diameter, weight of 40 g) implanted in a female southern river otter, which afterwards gave birth a pair of cubs, demonstrate that radiotransmitters do not affect the breeding and gestation processes (Medina-Vogel, pers. comm.). As the radiotransmitters implanted in marine otters functioned less time than the 8 mo indicated by the manufacturer and because they are probably the smallest described for otters to date, it could be advisable to develop a slightly larger transmitter for future radio-tracking studies with this species, if collection of data for a longer period is intended. Hernandez-Divers et al. (2001) recommend a lateral approach trough the paralumbar fossa to access the abdominal cavity. Nonetheless, the fact that more tissue is necessary to dissect, with a subsequently higher risk of haemorrhages, suggests that a midline approach trough the *linea alba* is safer. One benefit of the lateral approach is that the incision remains less exposed to water and fecal material during surgical recovery, decreasing the likelihood of wound contamination and subsequent infection. However, we did not experience this complication, probably due to the daily povidone-iodine flushes we implemented.

Although, our captivity facilities, followed the conditions for short term captivity of otters described before (Serfass et al., 1996; Kollias, 1999; Fernandez-Moran, et al. 2002), the mortality of three individuals with the same pathology, imply that marine otters, may be highly susceptible to stress. It has been described that the critical period for survivability of captive North American river otters is the first 72 hours (Kollias, 1999). Among the activities developed in our project, we also participated in the rescue and rehabilitation of orphan marine otters. Of these, a one-month-old male otter died suddenly with no apparent clinical signs. At post-mortem examination a massive blood clot which filled the whole stomach cavity was observed, and an acute ulcerative gastritis was diagnosed. Consequently, we recommend for future studies to increase housing size, incorporate the use of long acting neuroleptics and to restrict to a maximum both human-otter contact and length of captivity.

In conclusion, we recommend for the field veterinary management of marine otters: (1) the use of # 1.5 soft catch leg-hold traps for capture; (2) the use of ketamine 5.4 mg/kg and medetomidine 54 µg/kg, followed by atipamezole 236 µg/kg i.m. for short-term anaesthesia; (3) the ventral midline celiotomy for intra-abdominal radiotransmitter placement; and (4) the use of individual housing in a quarantine room, with the administration of a captivity protocol, for short term captivity. However, maximum caution must be taken in order to avoid or suppress stress-related events in marine otters.

**ACKNOWLEDGEMENTS** - This research was funded by the Dirección de Investigación of the Universidad Andrés Bello, the Rufford Small Grants for Nature Conservation, Earthwatch Institute, Idea Wild, and the National Zoo of Chile. We thank the Field Veterinary Program, Wildlife Conservation Society and the X<sup>th</sup> International Otter Colloquium organization committee, for its financial support to attend the present conference. We would like to thank also M. Fabry and P. Pascual for their contribution and logistic support.

## REFERENCES

- Alvarez, R., Medina-Vogel, G. (2008).** *Lontra felina*. In: IUCN 2011. IUCN Red List of Threatened Species. Version 2011.2. <[www.iucnredlist.org](http://www.iucnredlist.org)>. Downloaded on 12 December 2011.
- Arden-Clarke, C.H.G. (1986).** Population density, home range size and spatial organization of the Cape Clawless Otter, *Aonyx capensis*, in a marine habitat. *Journal of Zoology* **209**: 201-211.
- Arnemo, J.M. (1991).** Surgical implantation of intraperitoneal radiotelemetry devices in European river otters (*Lutra lutra*). *Habitat* **6**: 48-55.
- Blundell, G.M., Kern, J.W., Bowyer, R.T., Duffy, L.K. (1999).** Capturing river otters: a comparison of Hancock and leg-hold traps. *Wildlife Society Bulletin* **27**: 184-192.
- Durbin, L.S. (1998).** Habitat selection by five otters *Lutra lutra* in rivers of northern Scotland. *Journal of Zoology* **245**: 85-92.
- Dzialak, M.R., Serfass, T.L., Blakenship, T.L. (2001).** Reversible chemical restraint of fishers with medetomidine-ketamine and atipamezole. *Journal of Wildlife Management* **65**: 157-163.
- Erickson, D.W., McCullough, C.R. (1987).** Fates of translocated river otters in Missouri. *Wildlife Society Bulletin* **15**: 511-517.
- Fernandez-Mora, J., Perez, E., Sanmartin, M., Saavedra, D., Manteca-Vilanova, X. (2001).** Reversible immobilization of Eurasian otters with a combination of ketamine and medetomidine. *Journal of Wildlife Diseases* **37**: 561-565.
- Fernandez-Moran, J., Saavedra, D., Manteca-Vilanova, X. (2002).** Reintroduction of the Eurasian otter (*Lutra lutra*) in northeastern Spain: trapping, handling, and medical management. *Journal of Zoo and Wildlife Medicine* **33**: 222-227.
- Fournier-Chambrillon, C., Chusseau, J.P., Dupuch, J., Maizeret, C., Fournier, P. (2003).** Immobilization of free-ranging European mink (*Mustela lutreola*) and polecat (*Mustela putorius*) with medetomidine-ketamine and reversal by atipamezole. *Journal of Wildlife Diseases* **39**: 393-399.
- Garshelis, D.L., Siniff, D.B. (1983).** Evaluation of radio-transmitter attachment for sea otters. *Wildlife Society Bulletin* **11**: 378-383.
- Hernandez-Divers, S.M., Kollias, G.V., Abou-Madi, N., Hartup, B.K. (2001).** Surgical technique for intra-abdominal radiotransmitter placement in North American river otters (*Lontra canadensis*). *Journal of Zoo and Wildlife Medicine* **32**: 202-205.
- Hoover, J.P. (1984).** Surgical implantation of radiotelemetry devices in American river otters. *Journal of the American Veterinary Medical Association* **185**: 1317-1320.
- Hoover, J.P., Bahr, R.J., Nieves, M.A., Doyle, R.T., Zimmer, M.A., Lauzon, S.E. (1985).** Clinical evaluation and prerelease management of American river otters in the 2nd year of a reintroduction study. *Journal of the American Veterinary Medical Association* **187**: 1154-1161.
- Hoover, J.P., Root, C.R., Zimmer, M.A. (1984).** Clinical evaluation of American river otters in a reintroduction study. *Journal of the American Veterinary Medical Association* **185**: 1321-1326.
- Hussain, S.A., Choudhury, B.C. (1995).** Seasonal movement, home range and habitat use by smooth coated otters in National Chambal Sanctuary, India. *Habitat* **11**: 45-55.
- Jalanka, H.H., Roeken, B.O. (1990).** The use of medetomidine, medetomidine ketamine combinations, and atipamezole in nondomestic mammals - a review. *Journal of Zoo and Wildlife Medicine* **21**: 259-282.

- Kollias, G.V. (1999).** Health assessment, medical management, and prerelease conditioning of translocated North American river otters. In: *Zoo And Wild Animal Medicine*, **Fowler, M.E., Miller, R.E.** (eds.). W.B. Saunders Co., Philadelphia, Pennsylvania. pp. 443-448.
- Kreeger, T.J., Vargas, A., Plumb, G.E., Thorne, E.T. (1998).** Ketamine-medetomidine or isoflurane immobilization of black-footed ferrets. *Journal of Wildlife Management* **62**: 654-662.
- Kruuk, H. (2006).** Otters: ecology, behaviour and conservation. Oxford University Press, Oxford, United Kingdom.
- Larivière, S. (1998).** *Lontra felina*. *Mammalian Species*, **575**: 1-5.
- Lewis, J.C.M. (1991).** Reversible immobilization of Asian small-clawed otters with medetomidine and ketamine. *Veterinary Record* **128**: 86-87.
- Maze, M., Tranquilli, W. (1991).** Alpha-2 adrenoceptor agonists - defining the role in clinical anesthesia. *Anesthesiology* **74**: 581-605.
- Medina-Vogel, G., Bartheld, J.L., Pacheco, R.A., Rodriguez, C.D. (2006).** Population assessment and habitat use by marine otter *Lontra felina* in southern Chile. *Wildlife Biology* **12**: 191-199.
- Medina-Vogel, G., Boher, F., Flores, G., Santibañez, A., Soto-Azat, C. (2007).** Spacing behaviour of marine otters (*Lontra felina*) in relation to land refuges and fishery waste in Central Chile. *Journal of Mammalogy* **88**: 487-494.
- Medina-Vogel, G., Rodriguez, C.D. Alvarez, R.E., Bartheld, J.L. (2004).** Feeding ecology of the marine otter (*Lutra felina*) in a rocky seashore of the South of Chile. *Marine Mammal Science* **20**: 134-144.
- Melquist, W.E., Hornocker, M.G. (1983).** Ecology of river otters in West Central Idaho. *Wildlife Monographs*, **83**: 1-60.
- Miller, M., Weber, M., Neiffer, D., Mangold, B., Fontenot, D., Stetter, M. (2003).** Anesthetic induction of captive tigers (*Panthera tigris*) using a medetomidine-ketamine combination. *Journal of Zoo and Wildlife Medicine* **34**: 307-308.
- Mitchell-Jones, A.J., Jefferies, D.J., Twelves, J., Green, J., Green, R. (1984).** A practical system of tracking otters *Lutra lutra* using radiotelemetry and 65-Zn. *Lutra* **27**: 71-84.
- Muir, W.W., Hubbell, J.A., Skarda, R.T., Bednarski, R.M. (2001).** Veterinary Anesthesia. Harcourt, Madrid, Spain.
- Perrin, M.R., Carranza, I.D. (2000).** Habitat use by spotted-necked otters in the KwaZulu-Natal Drakensberg, South Africa. *South African Journal of Wildlife Research* **30**: 8-14.
- Ruiz-Olmo, J., Jimenez, J., Marco, I. (1991).** Radiotracking a translocated otter in Spain. *IUCN Otter Spec. Group Bull.* **6**: 6-7.
- Serfass, T.L., Brooks, R.P., Rymon, L.M. (1993a).** Evidence of long-term survival and reproduction by translocated river otters, *Lutra canadensis*. *Canadian Field-Naturalist* **107**: 59-63.
- Serfass, T.L., Brooks, R.P., Swimley, T.J., Rymon, L.M., Hayden, A.H. (1996).** Considerations for capturing, handling, and translocating river otters. *Wildlife Society Bulletin* **24**: 25-31.
- Serfass, T.L., Peper, R.L., Whary, M.T., Brooks, R.P. (1993b).** River otter (*Lutra canadensis*) reintroduction in Pennsylvania, prerelease care and clinical evaluation. *Journal of Zoo and Wildlife Medicine* **24**: 28-40.
- Sjöåsen, T. (1997).** Movements and establishment of reintroduced European otters *Lutra lutra*. *Journal of Applied Ecology* **34**: 1070-1080.
- Somers, M.J., Nel, J.A.J. (2004).** Habitat selection by the Cape clawless otter (*Aonyx capensis*) in rivers in the Western Cape Province, South Africa. *African Journal of Ecology* **42**: 298-305.
- Soto-Azat, C., Reyes, R., Medina-Vogel, G. (2004).** Reversible immobilization and anesthesia using ketamine and medetomidine in otters in Chile. Proceedings IXth International Otter Colloquium, June 4-10th, 2004, Frostburg, MD, USA. *IUCN Otter Spec. Group Bull.* **21A**
- Soto-Azat C., Sepúlveda, M., Medina-Vogel, G. (2006).** Aspectos veterinarios en huillines capturados: antecedentes, consideraciones y propuestas para un adecuado manejo. In: **Cassini M.H., Sepúlveda, M.** (eds.). El Huillín *Lontra provocax*: Investigaciones sobre una nutria patagónica en peligro de extinción. Serie Fauna Neotropical 1, Publicaciones de la Organización PROFAUNA, Buenos Aires. pp:147-152.
- Soto-Azat, C., Boher, F., Flores, G., Mora, E., Santibañez, A., Medina-Vogel, G. (2006).** Reversible anesthesia in wild marine otters (*Lontra felina*) using ketamine and medetomidine. *Journal of Zoo and Wildlife Medicine* **37**: 535-538.
- Spelman, L.H. (1999).** Otter anesthesia. In: **M.E. Fowler, Miller, R.E.** (eds.). Zoo and wild animal medicine, W.B. Saunders Co., Philadelphia, Pennsylvania. pp. 436-443
- Spelman, L.H., Sumner, P.W., Levine, J.F., Stoskopf, M.K. (1993).** Field anesthesia in the North-American river otter (*Lutra canadensis*). *Journal of Zoo and Wildlife Medicine* **24**: 19-27.

**Spelman, L.H., Sumner, P.W., Levine, J.F., Stoskopf, M.K. (1994).** Anesthesia of North-American river otters (*Lutra canadensis*) with medetomidine-ketamine and reversal by atipamezole. *Journal of Zoo and Wildlife Medicine* **25**: 214-223.

## **RÉSUMÉ**

### **GESTION VÉTÉRINAIRE DE LA LOUTRE MARINE (*Lontra felina*) DANS LES ETUDES ECOLOGIQUES AU CHILI**

La Loutre marine (*Lontra felina*) est une espèce de loutre d'Amérique du Sud très peu étudiée malgré un état de conservation préoccupant. Entre 2004 et 2006 dans le cadre d'études par radio-télémetrie, d'études génétiques et vétérinaires, 16 loutres marines (10 mâles et 6 femelles), avec une masse corporelle moyenne de  $3,8 \pm 0,3$  kg, ont été piégées sur la côte centrale et sud du Chili. Vingt procédures d'anesthésie ont été testées incluant les immobilisations et l'anesthésie pour les implantations chirurgicales d'émetteurs. Nous avons utilisé un anesthésiant intramusculaire combinant kétamine (5 mg/kg) et médétomidine (50 µg/kg). Nous n'avons eu que quelques complications mineures dont une légère hypothermie et de l'hypoxémie. Après  $47 \pm 10$  min, l'anesthésique a été inhibé par voie intramusculaire par de l'atipamézole ( $236 \pm 38$  mg/kg). Le réveil total est atteint après  $12,0 \pm 6,2$  min. Six loutres (trois mâles et trois femelles) ont été soumises à l'implantation chirurgicale d'un émetteur par laparotomie médiane et ventrale. Ces individus ont été placés dans une salle de quarantaine dans des cages grillagées (0,9 m de long x 0,4 m de large x 0,48 m de haut), elles-mêmes connectées à des tubes en PVC (1 m de long x 0,4 m de diamètre) faisant office de catiches. Tout comme en captivité, l'alimentation est constituée d'athérines fraîches (*Odontesthes regia*), de plusieurs espèces de crabes et de poissons locaux. Pendant leur période préopératoire, ces individus ont aussi bénéficié d'un protocole vétérinaire captif comprenant l'administration d'enrofloxacin, de kétoprofène, d'ivermectine et de suppléments vitaminiques. Trois loutres sont mortes en captivité et leurs examens post-mortem ont révélé des gastrites ulcérées modérées à sévères. Aucune des loutres implantées n'a présenté de complications et la cicatrisation complète est apparue à  $13 \pm 3$  jours au moment où les animaux ont été libérés. Pendant le suivi des loutres par radiopistage, nous avons observé leur bonne appropriation de leur domaine vital.

### **RESUMEN: MANEJO VETERINARIO DEL CHUNGUNGO (*Lontra felina*) EN ESTUDIOS ECOLÓGICOS EN CHILE**

El chungungo (*Lontra felina*) es una poco estudiada nutria Sudamericana con problemas de conservación. Entre los años 2004 y 2006, 16 chungungos (10 machos y seis hembras), con una masa corporal promedio de  $3,8 \pm 0,3$  kg, fueron capturados en la costa centro-sur de Chile, como parte de estudios de radiotelemedría, genética y aspectos veterinarios. Veinte procedimientos anestésicos fueron evaluados, incluyendo inmovilizaciones químicas y anestésias para la implantación quirúrgica de radiotransmisores. Se utilizó una combinación anestésica de ketamina 5 mg/kg y medetomidina 50 µg/kg i.m. Complicaciones menores incluyeron hipotermia e hipoxemia leves. Después de  $47 \pm 10$  min, la anestesia fue antagonizada con atipamezol  $236 \pm 38$  µg/kg i.m. La recuperación anestésica total se alcanzó a los  $12,0 \pm 6,2$  min. Seis nutrias (tres machos y tres hembras) fueron sometidas a la implantación quirúrgica de radiotransmisores a través en una celiotomía en la línea ventral. Estos individuos fueron mantenidos al interior de una sala de cuarentena, en jaulas metálicas individuales (0,9 m largo x 0,4 m ancho x 0,48 m alto), unidas a un

tubo de PVC que sirvió de madriguera (1 m largo x 0,4 m diámetro). Una vez en cautiverio, la dieta consistió en pejerrey fresco (*Odontesthes regia*), sumado a una variedad de peces y cangrejos de las mismas áreas. Estos individuos durante su periodo de aclimatación, previo a la cirugía, recibieron un protocolo que incluyó la administración de enrofloxacino, ketoprofeno, ivermectina y suplementos vitamínicos. Tres nutrias murieron en cautiverio, en las cuales se diagnosticó al examen postmortem, gastritis ulcerativas severas y moderadas. Ninguna de las nutrias operadas tuvo complicaciones quirúrgicas y la cicatrización de la herida se completó a los  $13 \pm 3$  días, momento en que las nutrias fueron liberadas. Durante el monitoreo a través de radiotelemetría, todas las nutrias fueron capaces de establecerse en sus ámbitos de hogar.