

ARTICLE

VASCULARIZATION OF THE AORTIC ARCH IN  
NEOTROPICAL OTTER (*Lontra longicaudis*, OLFERS 1818)

Procassia M. L. BARBOSA<sup>1,2</sup>, Pricila S. ESTEVES<sup>2</sup>, Alan L. SANTOS<sup>1</sup>,  
Oldemar CARVALHO JUNIOR<sup>2</sup>

<sup>1</sup>Universidade Federal de Santa Catarina; Departamento de Zootecnista e Desenvolvimento Rural,  
Rod. Admar Gonzaga, s/n, Itacorubi-SC

<sup>2</sup>Instituto Ekko Brasil, Servidão Euclides João Alves, S/N, Lagoa do Peri, 88066-000, Florianópolis,  
SC, Brazil. e-mail: [atendimento@ekkobrasil.org.br](mailto:atendimento@ekkobrasil.org.br)



(Received 5<sup>th</sup> October 2020, accepted 6<sup>th</sup> December 2020)

**Abstract:** *Lontra longicaudis* is a semi-aquatic carnivorous mammal that belongs to the Mustelidae family and Lutrinae subfamily. It is found in South and Central America, from southern Mexico to Uruguay and up to 3,000 m altitude. In this study, vascularization of the aortic arch is described in the neotropical otter. Eight animals were studied, three puppies and five adults from the Otter Project of the Instituto Ekko Brasil. The results indicate that the brachiocephalic trunk and the left subclavian artery originated from the aortic arch in all animals studied. This pattern is similar to that found in wild and domestic carnivores. The brachiocephalic trunk arises three arteries, the left common carotid artery, the right common carotid artery, and the right subclavian artery, the latter two being emitted from a common trunk. The right and left subclavian arteries give origin to five vessels represented by the vertebral artery, the superficial cervical artery, the internal thoracic artery, the costocervical trunk, and the axillary artery.

**Citation:** Barbosa, P.M.L., Esteves, P.S., Santos, A.L. and Carvalho Junior, O. (2021). Vascularization of the Aortic Arch in Neotropical Otter (*Lontra longicaudis*, Olfers 1818). *IUCN Otter Spec. Group Bull.* **38** (3): 173 -182

**Keywords:** physiology; morphology; carnivorous; Mustelidae

## INTRODUCTION

Despite numerous publications on *Lontra longicaudis*, there is still little information about its anatomy, morphology and physiology. Most studies concern the diet (Quadros and Monteiro-Filho, 2001; Uchôa et al., 2004; Quintela et al., 2008; Carvalho-Junior et al., 2010a, 2010b; Rheingantz et al., 2011), conservation status (Rodrigues, 2013) or the geographic distribution (Carvalho-Junior et al., 2012).

Energy analysis and economic evaluation of the otter was carried out by Carvalho Junior (2016). Knowledge of morphological aspects is essential in determining diversity, adaptation, and intra-specific variability. This work aims to investigate the origin of the collateral branches of the aortic arch.

The circulatory system is responsible for transporting blood through tissues, bringing oxygen and nutrients to different areas of the body, and collecting the carbon

dioxide that results from cellular metabolites. The aortic artery is the main vessel that distributes arterial blood to all systems. The head, neck, chest cavity, and chest organs are supplied with blood from the arteries that emerge from the aortic arch. Knowing the distribution and behavior of the arteries that originate from the aortic arch contributes to the understanding of the morphology, compared anatomy, and the clinic and surgery of wild animals.

The origin of the collateral branches that emerge from the aortic arch assumes a varied disposition between domestic and wild animals. These variations are already well described (Nickel et al., 1981; Sisson et al., 1975; Barone, 2010; Dyce et al., 2017; König and Liebich, 2020).

Studies with several species have shown a varied disposition in distributing the arteries that emerge from the aortic arch in wild animals. Among the species studied, *Agouti paca* (Oliveira et al., 2001), *Didelphis albiventris* (Reckziegel et al., 2003, Schimming et al., 2016), *Chinchilla lanigera* (Araújo et al., 2004), *Hydrochoerus hydrochaeris* (Culau et al., 2007), *Kerodon rupestris* (Magalhães et al., 2007), *Lepus europaeus* (Brudnicki et al., 2007), *Myocastor coypus* (Campos et al., 2010), *Mazama gouazoubira* (Schimming et al., 2012), *Tamandua tetradactyla* (Pinheiro et al., 2012), *Ozotoceros bezoarticus*, *Mazama gouazoubira* and *Axis axis* (Perez and Erdogan, 2014), *Galea spixii* (Oliveira et al., 2015), and *Callithrix penicillata* (Souza Neto et al., 2019).

Publications with *Procyon cancrivorus* (Santos et al. 2004), *Leopardus pardalis* (Martins et al., 2010), *Mustela* sp. (Quesenberry and Carpenter, 2012; Fox and Marini, 2014), *Cerdocyon thous* (Engel et al., 2013; Lima et al., 2016), and *Lontra canadensis* (Baitchman and Kollias, 2020), demonstrate that the origin of the collateral branches of the aortic arch maintains the same pattern observed for domestic carnivores. However, there are some variations between species, as Engel et al. (2013) mentioned for *Cerdocyon thous*.

## METHODS

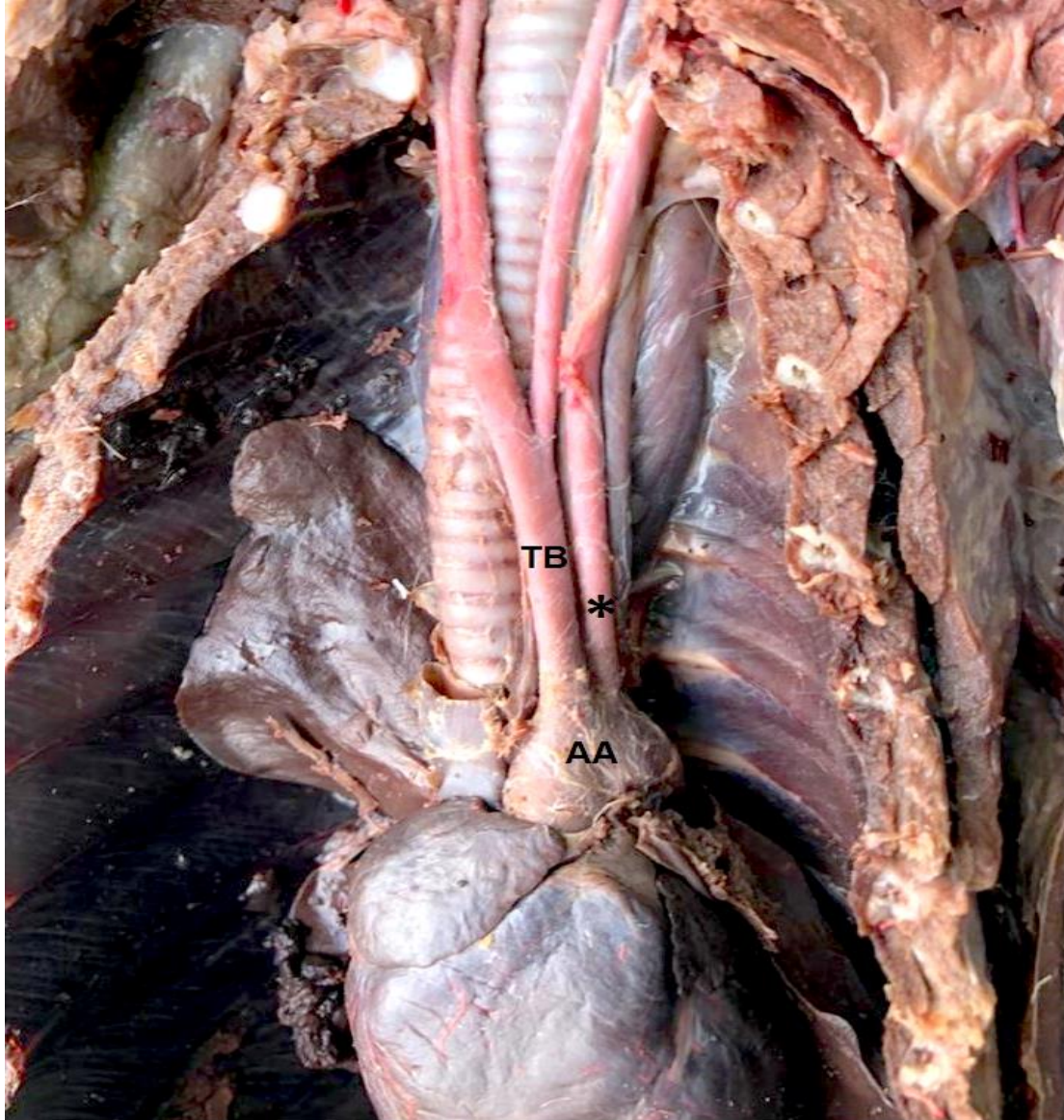
This study was conducted at the Animal Refuge Research Laboratory of the Instituto Ekko Brasil in partnership with the Wild Animals Research Laboratory at the Federal University of Santa Catarina (LAPAS/UFSC). The project's methodology for processing otters was authorized by the Animal Use Ethics Committee (CEUA/UFSC), process 23091.001975/10-24. Eight *Lontra longicaudis* were used, three female offspring, one adult male, and four adult females. All animals are part of the scientific collection of Instituto Ekko Brasil and were found dead by residents, run over by cars, drowned in fishing traps, or retaliation by fishermen, and stored at -20 °C until necropsies were performed.

The animals were thawed, and the left common carotid artery was cannulated to fill the arterial vascular system with Latex Neoprene 450, stained in red. Subsequently, the animals were fixed in a 10% aqueous formaldehyde solution. After fixation, specimens were dissected, and access to the thoracic cavity was done through the lateral opening of the ribs and the sternum's removal.

The adjacent structures were dissected, and the vessels were identified. Schematic drawings were made for each vascular system, and the most representative specimen photographed for documentation. The study was based on the nomenclature adopted by the International Committee on Veterinary Gross Anatomical Nomenclature (2017).

## **RESULTS**

In the eight animals studied, the brachiocephalic trunk represented the first branch of the aortic arch, followed by the left subclavian artery as independent branches (Fig. 1). The branches originating from these arteries also did not show variations between the analyzed specimens.

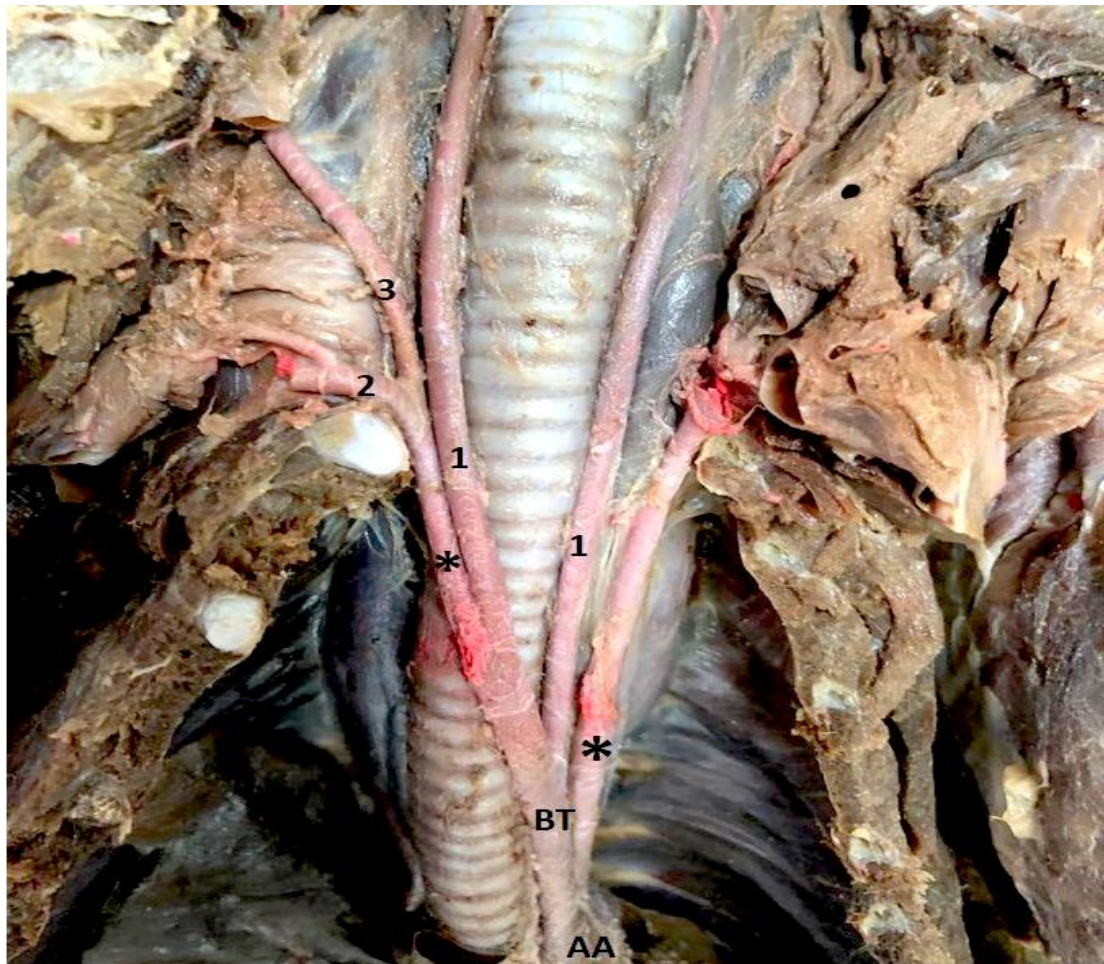


**Figure 1.** View of the aortic arch and its branches. AA - Aortic arch; TB - Brachiocephalic trunk; \*Aa. Subclavian artery

The internal thoracic artery appeared at the level of the first intercostal space, inside the thoracic cavity, and advanced in the caudoventral direction towards the sternum and transverse muscle of the chest. At the chest entrance, the right and left subclavian arteries branched into two arteries, the superficial cervical artery that supplies the cervical musculature's ventrolateral surface, and the axillary artery that supplies the muscles of the thoracic limbs.

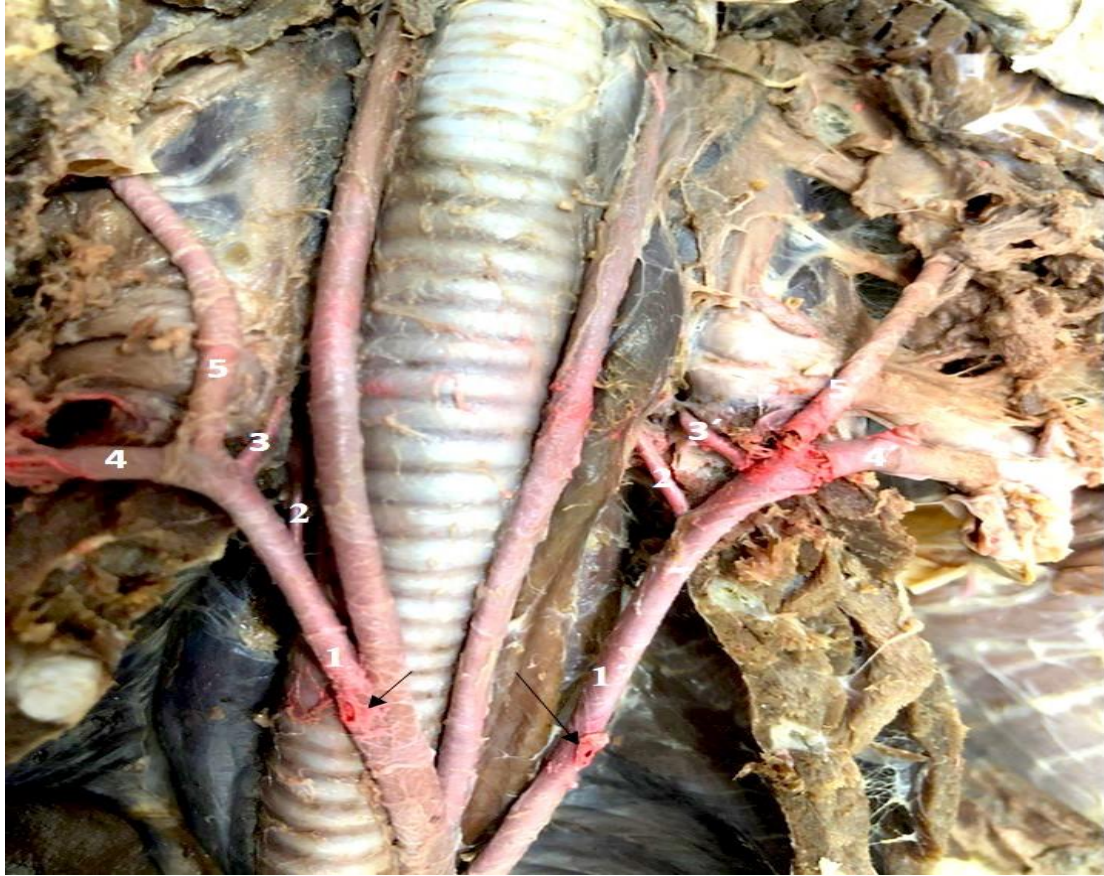
The brachiocephalic trunk followed cranially over the trachea's ventral face and emitted three branches, the left common carotid artery, the right common carotid artery, and the right subclavian artery.

In all specimens studied, the left common carotid artery was the first branch emitted by the brachiocephalic trunk, followed by the formation of a common trunk that originated the right common carotid artery and the right subclavian artery at the level of the first intercostal space, in the right antimere of the thoracic cavity (Fig. 2).



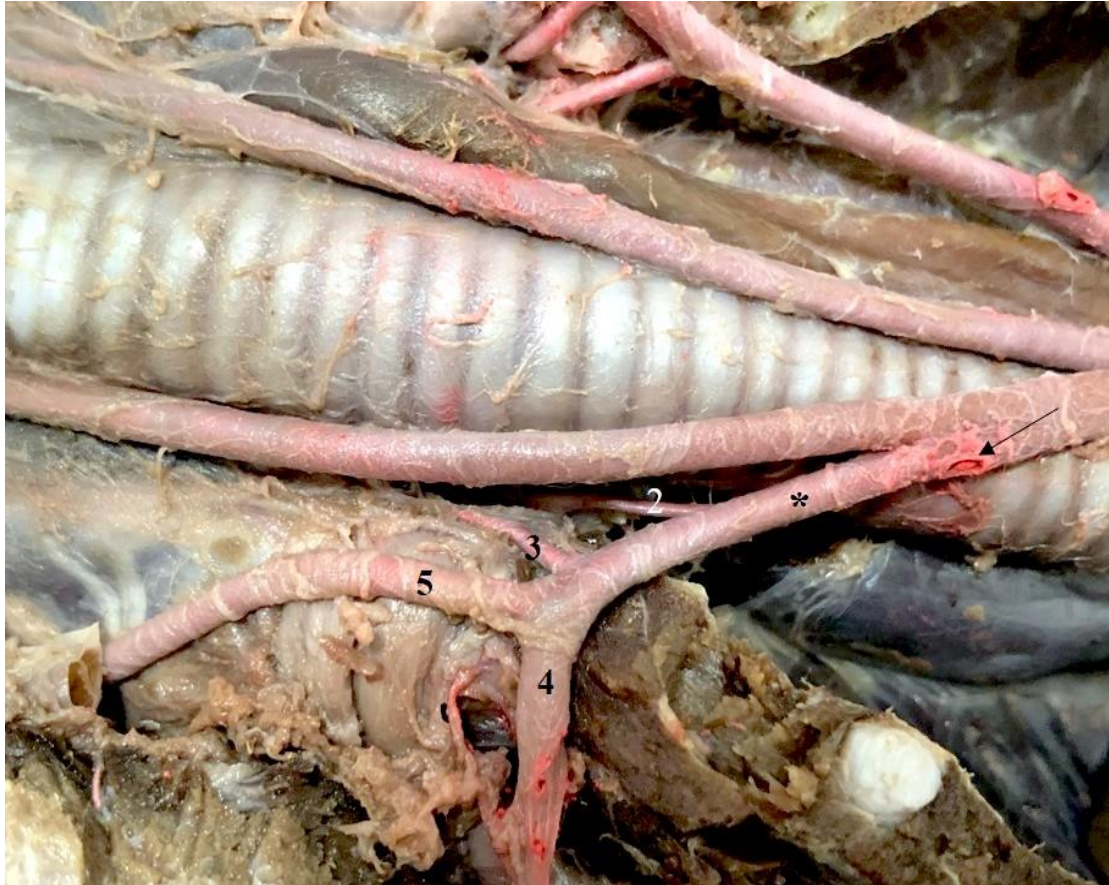**Figure 2.** View of the brachiocephalic trunk and its branches. 1- common carotid artery; 2- axillary artery; 3 - superficial cervical artery; AA - aortic arch; BT - brachiocephalic trunk; \* subclavian artery.

In the eight animals analyzed the right and left subclavian arteries emitted five branches: the vertebral artery, the costocervical trunk, the internal thoracic artery, the superficial cervical artery, and the axillary artery (Fig. 3).



**Figure 3.** View of the subclavian arteries and their branches. 1 - right subclavian artery; 1' - left subclavian artery; arrows - right internal thoracic artery; 2 - right vertebral artery; 2' - left vertebral artery; 3 - right costocervical trunk; 3' - left costocervical trunk; 4 - right axillary artery; 4' - left axillary artery; 5 - right superficial cervical artery; 5' - left superficial cervical artery.

The vertebral artery went craniodorsally towards the cervical vertebrae. The costocervical trunk originated from the subclavian right after the vertebral artery and proceeded to the cervical region's dorsal muscles and the chest (Fig. 4).



**Figure 4.** View of the right subclavian artery and their branches in the cranial part of the thoracic cavity. \*1 - right subclavian artery; arrow - right internal thoracic artery; 2 - right vertebral artery; 3 - right costocervical trunk; 4 - right axillary artery; 5 - right superficial cervical artery.

## DISCUSSION

The study of anatomy in domestic animals shows that the origin of the vessels that emerge from the aortic arch varies according to species, and the same occurs in wild animals. Considering the carnivorous order, the treatises on animal anatomy (Nickel and Seiferle, 1981; Sisson et al, 1975; Barone, 1996; Dyce et al., 2019; König and Liebich, 2020), describe that the aortic arch gives rise to the brachiocephalic trunk and then to the left subclavian artery. This same disposition was verified in this study, as well as in *Lontra canadensis* (Baitchman and Kolle, 2000), in *Procyon cancrivorus* (Santos et al., 2004), in *Mustela* sp. (Fox and Marini, 2014; Quesenberry and Carpenter, 2020) *Leopardus pardalis* (Martins et al., 2010), and in *Cerdocyon thous* (Lima et al., 2016).

With the results obtained in this work, it is possible to suggest a pattern in the origin of the vessels that emerge from the aortic arch in carnivores, whether wild or domestic, although variations may occur. Example for such variation are cases mentioned by Culau et al. (2004), when they reported the ectopic origin of the right subclavian artery and the bicarotid trunk in a dog, and by Engel et al. (2013) studying *Cerdocyon thous*, originating from a bicarotid trunk in the aortic arch.

In the neotropical otter, the origin and disposition of the arteries in the brachiocephalic trunk is following that described for domestic carnivores (Sisson et al, 1985; Nickel et al., 2010; Dyce, 2017; König and Liebich, 2020), where the brachiocephalic trunk first originates the common carotid artery left and posteriorly the right common carotid arteries and the right subclavian artery.

A study carried out with *Leopardus pardalis* (Martins et al., 2010) presented these same results. However, Santos et al. (2004), studying a specimen of *Procyon cancrivorus*, report that the brachiocephalic trunk of this species undergoes a trifurcation at the level of the first intercostal space, in the left antimer of the thoracic cavity, originating the left and right common carotid arteries, and the right subclavian artery. Indeed, Sisson et al (1975) mentions that the brachiocephalic trunk may present this trifurcation in domestic carnivores.

In *Cerdocyon thous* (Lima et al. 2016), the brachiocephalic trunk first originated the right subclavian artery and followed in a bicarotid trunk typical right and left carotid arteries. Filho and Borelli (1970), in a study with 240 cats (*Felis catus domestica*), reported that 75 animals showed the formation of the bicarotid trunk.

Wild carnivores work evidenced the dispositions described in the treatises of animal anatomy and comparative anatomy for the origin of the vessels' brachiocephalic trunk in domestic carnivores. The arrangement found in *Lontra longicaudis* and *Leopardus pardalis* were the same as those mentioned for domestic animals. These animals have a standard trunk between the right common carotid and right subclavian arteries after the left common carotid artery's origin.

In the carnivorous order such as *Lontra canadensis* (Baitechman and Kollias, 2020), *Leopardus pardalis* (Martins et al., 2010) and *Cerdocyon thous* (Lima et al., 2016), the subclavian arteries gave rise to the collateral branches: vertebral artery, costocervical trunk, internal thoracic artery, superficial cervical artery and axillary artery, the same branches found in our study. This same origin was also mentioned in *Mustela* sp. (Fox and Marini, 2014; Quesenberry et al., 2020). However, Santos et al. (2004) did not mention the vertebral artery and the axillary artery as branches originating from the subclavias in *Procyon cancrivorus*. Our results align with what is described in the literature for dogs and cats (Filho and Borelli, 1970; Sisson et al, 1975; Dyce et al., 2019; König and Liebich, 2020).

This work describes the organization of the branches that originate from the aortic arch in a neotropical otter and notes that the origin of these vessels is similar to that described for domestic carnivores, and for wild carnivores. In carnivores in general, the brachiocephalic trunk and the left subclavian artery emerge directly from the aortic arch. Thus, we can conclude that this pattern of origin of vascularization of the aortic arch is shared, both for domestic carnivores and wild carnivores.

## REFERENCES

- Araújo, A.C.P., Oliveira, J.C.D., Campos, R. (2004).** Collaterals branches of the aortic arch and its main rami in chinchilla (*Chinchilla lanigera*). *Revista Portuguesa de Ciências Veterinárias*, **99**: 53-58.
- Baitechman, E.J., Kollias, G.V. (2000).** Clinical anatomy of the North American river otter (*Lontra canadensis*). *Journal of Zoo and Wildlife Medicine: Official Publication of the American Association of Zoo Veterinarians*, **31**: 473-483.
- Barone, R. (1996).** Anatomie comparée des mammifères domestiques. Tome 5: Angiologie. Paris: Vigot, 1996.
- Brudnicki, W., Macherzynska, A., Nowicki, W. (2007).** Variation in the arteries of the aortic arch in European Brown Hare (*Lepus europaeus*). *Electronic Journal Polish Agricultural Universities*, **10**(1). <http://www.ejpau.media.pl/volume10/issue1/art-03.html>. Last accessed: 1.5.2020.

- Campos, R., Araújo, A.C.P., Azambuja, R.C. (2010).** Ramos colaterais do arco aórtico e suas principais ramificações em nutria (*Myocastor coypus*). *Acta Scientiae Veterinariae*, **38**: 139-146.
- Carvalho-Junior, O. (2016).** Emery Analysis of the Peri Lake System and the Role of the Neotropical Otter. *IJRRAS*, **29**: 31-54.
- Carvalho-Junior, O., Birolo, A.B., Macedo-Soares, L. (2010).** Ecological Aspects of Neotropical Otter (*Lontra longicaudis*) in Peri Lagoon, South Brazil. *IUCN Otter Spec. Group Bull.*, **27**: 105-115.
- Carvalho-Junior, O., Macedo-Soares, L., Birolo, A.B. (2010).** Annual and interannual food habits variability of a Neotropical otter (*Lontra longicaudis*) population in Conceição Lagoon, South of Brazil. *IUCN Otter Spec. Group Bull.*, **27**: 24-32.
- Carvalho-Junior, O., Filippini, A., Salvador, C.H. (2012).** Distribution of neotropical otter, *Lontra longicaudis* (Olfers, 1818) (Mustelidae) in coastal islands of Santa Catarina, Southern Brazil. *IUCN Otter Spec. Group Bull.*, **29**: 95-108.
- Culau, P.O.V., Oliveira, J.C.D., Reckziegel, S.H., Lindemann, T. (2004).** Origem ectópica da artéria subclávia direita e do tronco bicarotídeo no cão. *Ciência Rural*, **34**: 1615-1618.
- Culau, P.O.V., Reckziegel, S.H., Lindemann, T., Araújo, a. C. P.; Balzaretto, F. (2007).** Colaterais do arco aórtico da capivara (*Hydrochoerus hydrochaeris*). *Acta Scientiae Veterinariae*, **35**: 89-92.
- Dyce, K.M., Sack, W.O., Wensing, C.J.G. (2009).** Textbook of Veterinary Anatomy. [s.l.]: Elsevier Science Health Science Division.
- Engel, S., Maiochi, R.R., Birck, A.J., Filadelpho A.L., Guimarães, G.C. (2013).** Origem e distribuição do arco aórtico do cachorro-do mato (*Cerdocyon thous*). *Revista Científica Eletrônica de Medicina Veterinária*, **11**(21).
- Filho, A.F., Borelli, V. (1970).** Contribuição ao estudo dos colaterais calibrosos do arco aórtico no gato. *Revista da Faculdade de Medicina Veterinária*, **8**: 385-388.
- Fox, J., Marini, R.P. (2014).** Biology and Diseases of the Ferret. 3.ed. [s.l.]: Wiley-Blackwell.
- International Committee on Veterinary Gross Anatomical Nomenclature. (2017).** Nomina Anatomica Veterinaria. 6. ed. [s.l.]: Editorial Committee Hanover (Germany), Ghent (Belgium), Columbia, MO (U.S.A.), Rio de Janeiro (Brazil).
- 000König, H.E., Liebich, H. (Orgs.). (2020).** Veterinary Anatomy of Domestic Animals: Textbook and Colour Atlas. 7th Updated and Extended ed. Edição. Stuttgart; New York: Thieme Medical Publishers.
- Lima, A.R.; Souza, D.C.; Carmo, D.C. do; et al. (2016).** Ramos colaterais do arco aórtico e suas principais ramificações no cachorro-do-mato (*Cerdocyon thous*). *Pesquisa Veterinária Brasileira*, **36**: 647-651.
- Magalhães, M.D.S., Albuquerque, J.F.G., Oliveira, M.F., Papa, P.D.C., Moura, C.E.B. (2007).** Ramos do arco aórtico no mocó (*Kerodon rupestris*). *Revista Portuguesa de Ciências Veterinárias*, **102**: 49-52.
- Martins, D.M., Lima, A.R., Pinheiro, L.L., Brígida, S.S.S., Araújo, E.B., Melul, R., Lacreata Júnior, A.C.C., Meneses, A.M.C., Souza, A.C.B., Pereira, L.C. Fioretto, E.T., Branco, E. (2010).** Descrição Morfológica dos Ramos Colaterais do Arco Aórtico e suas Principais Ramificações em *Leopardus pardalis*. *Acta Veterinaria Brasilica*, **4**: 74-77.
- Nickel, R., Schummer, A., Seiferle, E. (1981).** Anatomy of the Domestic Animals. Berlin: Verlag Paul Parey.
- Oliveira, F.S., Machado, M.R.F., Miglino, M.A., Nogueira, T.M. (2001).** Gross anatomical study of the aortic ARC branches of the paca (*Agouti paca*, Linnaeus, 1766). *Brazilian Journal of Veterinary Research and Animal Science*, **38**: 103-105.
- Oliveira, R.E.M., Oliveira, G.B., Barbosa, P.M.L., Bezerra, F.V.F., Albuquerque, J.F.G., Ambrósio, C.E., Miglino, M.A., Oliveira, M.F. (2015).** Ramos colaterais do Arco aórtico do preá (*Galea spixii* Wagler, 1831). *Pesquisa Veterinária Brasileira*, **35**: 762-766.
- Pérez, W., Erdogan, S. (2014).** Arterial thoracic vascularization in some deer species: pampas deer (*Ozotoceros bezoarticus*), brown brocket deer (*Mazama gouazoubira*) and axis deer (*Axis axis*). *Anatomia, Histologia, Embryologia*, **43**: 490-494.
- Pinheiro, V.L.C., Lima, A.R., Pereira, L.C., Gomes, B.D., Branco, E. (2012).** Descrição anatômica dos ramos colaterais do arco aórtico do tamanduá-mirim (*Tamandua tetradactyla*). *Biotemas*, **25**: 133-137.
- Quadros, J., Monteiro-Filho, E.L.A. (2001).** Diet of the Neotropical Otter, *Lontra longicaudis*, in an Atlantic Forest Area, Santa Catarina State, Southern Brazil. *Studies on Neotropical Fauna and Environment*, **36**: 15-21.



- Quesenberry, K., Carpenter, J.W. (2011).** Ferrets, Rabbits and Rodents - E-Book: Clinical Medicine and Surgery. [s.l.]: Elsevier Health Sciences.
- Quintela, F.M., Porciuncula, R.A., Colares, E. (2008).** Diet of *Lontra longicaudis* (Olfers) in a coastal stream in southern Rio Grande do Sul State, Brazil. *Neotrop. Biol. Cons.*, **3**: 119-125.
- Reckziegel, S.H., Lindemann, T., Culau, P.O.V. (2003).** Collaterals of the aortic arch in opossum (*Didelphis albiventris*). *Ciência Rural*, **33**: 507-511.
- Rheingantz, M.L., Waldemarin, H.F., Rodrigues, L., Moulton, T.P. (2011).** Seasonal and spatial differences in feeding habits of the Neotropical otter *Lontra longicaudis* (Carnivora: Mustelidae) in a coastal catchment of southeastern Brazil. *Zoologia (Curitiba)*, **28**: 37-44.
- Rodrigues, L.A. (2013).** Avaliação do risco de extinção da Lontra neotropical *Lontra longicaudis* (Olfers, 1818) no Brasil. *Biodiversidade Brasileira*, **3**: 216-227.
- Santos, A.L.Q., Moraes, F.M., Malta, T.S., Carvalho S.F.M., Alves Júnior, J.R.F. (2004).** Topografia dos Colaterais Calibrosos do Arco Aórtico de um Mão - Pelada (*Procyon cancrivorus* GRAY, 1865) (Carnivora Procyonidae). *Archives of Veterinary Science*, **9**: 67-72
- Schimming, B.C., Matteis, R., Silva, J.R.C.P., Guazzelli Filho, J. (2012).** Ramos do arco aórtico no veado-catingueiro. *Revista Científica Eletrônica de Medicina Veterinária*, **10**: 1-8.
- Schimming, B.C., Jesus, L.S.B.S., Filadelfo, A.L. (2016).** Branching pattern of aortic arch in the white-eared opossum (*Didelphis albiventris*). *Braz. J. Vet. Res. Anim. Sci.* (Online), **53**: 235-242.
- Sisson, S., Grossman, J.D., Getty, R. (1975).** Anatomy of the Domestic Animals. 5ª Edição. Philadelphia: W B Saunders Co.
- Souza Neto, J.R.N. de, Lima, A.R., Branco, É. (2019).** Ramos colaterais do arco aórtico de *Callithrix penicillata* (É. Geoffroy, 1812) (Primates, Cebidae). *Biotemas*, **32**: 85-91.
- Uchôa, T., Vidolin, G.P., Fernandes, T.M., Velastin, G.O., Mangini, P.R. (2004).** Aspectos ecológicos e sanitários da lontra (*Lontra longicaudis* OLFERS, 1818) na Reserva Natural Salto Morato, Guaraqueçaba, Paraná, Brasil. *Cad. Biodivers.*, **4**: 19-28.

## RÉSUMÉ

### VASCULARISATION DE L'ARC AORTIQUE CHEZ LA LOUTRE À LONGUE QUEUE (*Lontra longicaudis*, OLFERS 1818)

*Lontra longicaudis* est un mammifère carnivore semi-aquatique appartenant à la famille des *Mustelidae* et à la sous-famille des *Lutrinae*. On la trouve en Amérique du Sud et en Amérique centrale, du sud du Mexique à l'Uruguay, jusqu'à 3000 m d'altitude. Dans cette étude, la vascularisation de l'arc aortique est décrite chez la loutre à longue queue. Huit animaux ont été étudiés, trois loutrons et cinq adultes du Projet Loutre de l'Institut Ekko Brasil. Les résultats indiquent que le tronc brachiocéphalique et l'artère sous-clavière gauche provenaient de l'arc aortique chez tous les animaux étudiés. Cet agencement est similaire à celui trouvé chez les carnivores sauvages et domestiques. Le tronc brachiocéphalique provient de trois artères: l'artère carotide commune gauche, l'artère carotide commune droite et l'artère sous-clavière droite, les deux dernières étant émises par un tronc commun. Les artères sous-clavières droite et gauche donnent naissance à cinq vaisseaux représentés par l'artère vertébrale, l'artère cervicale superficielle, l'artère thoracique interne, le tronc costocervical et l'artère axillaire.

## RESUMEN

### VASCULARIZACIÓN DEL ARCO AÓRTICO EN LA NUTRIA NEOTROPICAL (*Lontra longicaudis*, OLFERS 1818)

*Lontra longicaudis* es un mamífero carnívoro semi-acuático que pertenece a la familia *Mustelidae* y la subfamilia *Lutrinae*. Se encuentra en América del Sur y Central, desde México hasta Uruguay y hasta 3.000 m de altitud. En este estudio, se describe la vascularización del arco aórtico en la nutria neotropical. Se estudiaron ocho

animales, tres crías y cinco adultos, del Proyecto Nutria del Instituto Ekko Brasil. Los resultados indican que el tronco braquiocefálico y la arteria subclavia izquierda se originaron en el arco aórtico en todos los animales estudiados. Este patrón es similar al encontrado en carnívoros silvestres y domésticos. El tronco braquiocefálico origina tres arterias, la arteria carótida izquierda común, la arteria carótida derecha común, y la arteria subclavia derecha, siendo las dos últimas emitidas a partir de un tronco común. Las arterias subclavia derecha e izquierda dan origen a cinco vasos representados por la arteria vertebral, la arteria cervical superficial, la arteria torácica interna, el tronco costocervical, y la arteria axilar.

## **RESUMO**

### **VASCULARIZAÇÃO DO ARCO AÓRTICO EM LONTRA NEOTROPICAL (*Lontra longicaudis*, OLFERS 1818)**

*Lontra longicaudis* é um mamífero carnívoro semiaquático que pertence à família Mustelidae e à subfamília Lutrinae. É encontrada na América do Sul e Central, do sul do México ao Uruguai e até 3.000 m de altitude. Neste estudo, a vascularização do arco aórtico é descrita na lontra neotropical. Foram estudados oito animais do Projeto Lontra do Instituto Ekko Brasil, sendo três filhotes e cinco adultos. Os resultados indicam que, em todos os animais estudados, o tronco braquiocefálico e a artéria subclávia esquerda originam-se do arco aórtico. Este padrão é semelhante ao encontrado em carnívoros selvagens e domésticos. O tronco braquiocefálico origina três artérias, a artéria carótida comum esquerda, a artéria carótida comum direita, e a artéria subclávia direita, sendo as duas últimas emitidas a partir de um tronco comum. As artérias subclávias direita e esquerda dão origem a cinco vasos representados pela artéria vertebral, a artéria cervical superficial, a artéria torácica interna, o tronco costocervical e a artéria axilar.