

REPORT

INTERGROUP CONFLICT AND MYIASIS-INDUCED MORTALITY IN A GIANT OTTER FROM THE BRAZILIAN PANTANAL: IMPLICATIONS FOR POPULATION CONSERVATION

Greice Z. GONCHOROSKI,^{1,2} Abigail MARTIN,² Gabriela RAPHAEL,² Livia A. RODRIGUES,^{2,3} Mariana M FURTADO,² Guilherme M. MOURÃO,⁴ Caroline LEUCHTENBERGER^{2,5,6}

¹Universidade Federal do Rio Grande do Sul, Avenida Bento Gonçalves, 9090, Bairro Agronomia, 91540-000, Porto Alegre, RS, Brazil

²Projeto Ariranhas/Giant Otter Conservation Fund, Rua Presidente Vargas, 1319, Bairro Aimoré, 95940-000, Arroio do Meio, RS, Brazil

³Centro Nacional de Pesquisa e Conservação de Mamíferos Carnívoros, Instituto Chico Mendes de Conservação da Biodiversidade, CENAP/ICMBio, Estrada Municipal Hisaichi Takebayashi, 8600, Bairro da Usina, 12952-011, Atibaia, SP, Brazil

⁴Embrapa Pantanal, Laboratório de Vida Selvagem, Rua 21 de Setembro, 1880, 79320-900, Corumbá-MS, Brasil

⁵Instituto Federal Farroupilha - IFFAR, Alameda Santiago do Chile, 195, Nossa Sra. das Dores, 97050-685, Santa Maria, RS, Brazil

⁶IUCN Species Survival Commission, Otter Specialist Group, Mauverney 28, 1196 Gland, Switzerland
corresponding author: greicegonchoroskiz@gmail.com

(received 13th November 2024, accepted 10th December 2024)

Abstract: Agonistic encounters, characterized by confrontations and conflicts, have been documented across various animal taxa. Intraspecific conflicts are more common in socially structured populations such as the giant otter (*Pteronura brasiliensis*), a gregarious and territorial species. Here, we present the evolution of injuries resulting from a territorial dispute between two giant otter groups during the dry season in a disturbed touristic area in the Brazilian Pantanal. The injuries of a dominant male showed an unfavorable progression of a myiasis leading to the individual's death and implications for the social dynamics of the group and for conservation of the population.

Keywords: zoonosis; sociobiology; wildlife tourism; *Pteronura brasiliensis*

INTRODUCTION

Agonistic encounters, characterized by confrontations and conflicts, have been documented across various animal taxa, including both aquatic and semi-aquatic mammals (Simpson, 2000; Ribas and Mourão, 2004; Jacobs et al., 2008). Intraspecific conflicts can arise from territorial, sexual and parental disputes, as well as instances of parental-child aggression, and are more common in socially structured populations (De Dreu and Triki, 2022). Intergroup conflicts are energetically costly and can involve severe injuries and even the death of individuals and disruption of social units (Ribas and Mourão, 2004).

The giant otter (*Pteronura brasiliensis*) is an endangered member of the Mustelidae Family, endemic to South America. It is an apex predator in aquatic systems, known for being a gregarious and territorial species. Giant otter groups typically consist of a reproductive couple and non-reproductive helpers, and it can range

in size from two to 20 individuals. They engage in complex social interactions (Leuchtenberger and Mourão, 2008) and although the alpha males play a predominant role in group defense, usually every individual within the group participates in agonistic encounters with rivals. Therefore, both the group size and the health of the alpha males serve as proxies for the group's defense capacity. This capacity is essential for the survival of giant otter groups, enabling them to secure larger and better territories and positively impacts the reproductive success of the alpha couple (Leuchtenberger et al., 2015).

Agonistic encounters between giant otter groups seem to occur more frequently during the dry season in the Pantanal (Leuchtenberger et al., 2015), when resources are limited to the water bodies' channels, and it coincides with the breeding time. A strategy used by giant otters to mitigate such encounters is scent-marking the banks along the water bodies within their territorial boundaries (Leuchtenberger and Mourão, 2009) and/or using vocalizations (calls) to advertise their presence to the neighboring group (Leuchtenberger et al., 2015; Potts et al. 2019). Nevertheless, it's noteworthy that this behavior does not prevent territorial overlap (Leuchtenberger et al., 2015). These agonistic interactions are aggressive, noisy, and risky (Ribas and Mourão 2004; Schweizer, 1992), as the species is equipped with sharp canines and claws that can cause lethal injuries (Rosas and Mattos, 2003). However, the evolutionary path of injuries leading to death remains unexplored.

Here, we present for the first time the evolution of myiasis resulting from a lesion caused by a territorial dispute in a giant otter, ultimately leading to the individual's death. This report highlights the implications for both individual health and social dynamics within the population, with significant implications for conservation efforts.

METHODS

The study area is located in the Northern Pantanal, Brazil, within the 'Encontro das Águas State Park' (56°W 39' 54", 17°S 14' 58"). The park is known as a prime location for jaguar safaris, attracting numerous tourist boats daily and providing ample opportunities to observe wildlife behaviors. The climate of the Pantanal is humid and tropical, characterized by hot, rainy summers and dry, sunny winters.

Between 2019 and 2023 a group of giant otters (hereafter referred to as G4) established their territory in this area. They were systematically observed during our population monitoring, as well as by tourist guides and professional photographers. The animals were identified using their individual throat pattern. The date and GPS coordinates of each observation were recorded to analyze their spatial movements and photographs were taken to document the group's behavior. Research activities were conducted with federal and state permits (SISBIO 85851-1, SEMA-MT-2017/2022).

RESULTS

During the five years of monitoring, the male named "Pai" and female named "Petri" endured as the reproductive couple of G4. The group size varied from three to seven individuals during this time (Supplementary Figure 1). In mid-2023, it finally split into two groups: one composed only by "Pai", "Petri" plus one adult male (named "A"); and another, composed by two otters, originated from G4 (the male "Nick", and the female "Starfish"). This second group established its territory nearby.

On July 11th, 2023, during the dry season, "Pai", "Petri" and "A" were observed fighting against an unknown giant otter group of four adults (Fig. 1A). Following the aggressive interaction, on the same day, "Pai" was observed with wounds and irregular lacerations on the right side of the face below the eye, extending to the mouth (Fig. 2A).

Flies could be observed landing close to injuries (Fig. 1B). Days later, we could also observe that Pai's scrotal sac exhibited a lacerating injury with the testicle exposed (Fig. 2B). The dominant female "Petri" had a small wound on its right front limb (Fig. 2C), while the subordinate male "A" had injuries on the front left paw with a marked difficulty in putting weight on it (Fig. 2D).




Figure 1. Timeline presenting the progress of the myiasis of a dominant giant otter male, after an agonistic encounter that occurred on July 11th 2023, in the Brazilian Northern Pantanal. (photo credits: A, B, C: Gustavo Gapari; D: Fabio Arruda/Barong House; E, F: Mark Thomas; G: Daniel De Granville; I: Cesar Moraga).

During subsequent monitoring, the injuries of "Pai" showed an unfavorable progression. On July 23th, his neck and head, which had previously been covered by fur, demonstrated a significant increase in swelling extending from the left ear to the ventral region, with four deep punctures and lacerations present (Fig. 1C).

In a new sighting, on July 30th, the animal was seen resting outside of the water, uncovering previously unnoticed lesions and a reduction in body condition score (Fig. 2B). Furthermore, abrasions were noticed on the cutaneous tissue on the left side of the neck (Fig. 2B). On the right side of the neck there was a reduction in edema, and the penetrating injuries showed an expansion in the connecting margins, resulting in two large openings in the tissue (Fig. 1D).

On August 7th, Pai's monitored injury on the neck showed almost complete reduction (Fig. 1E); there was no presence of edema, and the fur covered the site. A new affected area was seen on the animal's back, with a circular, deep opening containing larvae inside. Connected to the larger lesion, there are small punctate openings surrounding the affected area. Further down, new circular openings with larval infestation were present. From another angle, round and poorly defined regions of increased volume were found on the animal's back (Fig. 1F). The pattern and origin of the injury suggested new areas with the presence of myiasis, still covered by fur.

On August 11th, hypertrophic scar tissue, with irregular hairless edges was seen on the animal's head, along with complete healing of primary lesions. The same scar pattern could be seen on the paws while holding a fish (Fig. 1G). Nevertheless, the main area affected by myiasis infestation on the back showed a rapid increase in size, with more larvae, hypopigmentation, and significant loss of tissue structure (Fig 1H).



Figure 2. Injuries reported for a group of giant otters after an agonistic encounter on July 11th 2023, in the Brazilian Northern Pantanal. A: The dominant male “Pai” presents wounds with irregular lacerations on the right side of the face below the eye, extending to the mouth (photo: Gustavo Gaspari). B: The scrotal sac of “Pai” exhibited a lacerating injury, exposing the testicle (photo: Fabio Arruda/Barong House). C: The dominant female “Petri” had a wound on her right limb (photo: Fabio Arruda/Barong House); and D: The subordinate male “A” had injuries on his left front paw (photo: Fabio Arruda/Barong House).

In the last encounter, on August 12th, “Pai” was observed alone and outside the territory border of its original group. The initial infested area exhibited a larger extension, with larvae in numerous stages and sizes, accompanied by hemorrhage and loss of adipose and muscular tissue. New sites with larval presence were observed, with lesions continuously growing and becoming purulent through the parasites' feeding (Fig. 1I). This was the last observation of the individual.

On August 8th, the subordinate male “A” was observed scent-marking the territory more frequently than usual. By August 14th, the male “Nick” left his partner and joined “Petri” and “A”, taking over the dominant position from that point forward.

On August 9th, two cubs were seen coming out of the den, estimated to be around 3 weeks old. Unfortunately, by mid-September, the cubs were last seen, indicating the loss of the offspring from the original G4 couple.

DISCUSSION

Our results showed that injuries resulting from conflicts among animals in their natural environment have the potential for unfavorable consequences, including

infections, tissue function loss, parasitic infestations and the death of individuals.

The affected otter in our study displayed a range of distressing clinical findings that persisted for nearly a month until its disappearance. These findings included loss of body condition, continuous bleeding in areas infested by larvae, the increase of lesions, and tissue loss due to larval feeding. The prolonged duration of these afflictions highlights the severe impact on the otter's health. These injuries not only led to potential secondary infections but also could have induced significant pain. Our study further contributes to the understanding of myiasis evolution and potentially lethal consequences of giant otter territorial disputes.

The main dipteran responsible for causing myiasis in wild and domestic animals in Brazil is *Cochliomyia hominivorax*, known as the New World screwworm (Costa-Júnior et al., 2019). This parasitic infestation also plays an important role in public health as a zoonotic disease in South America. The parasite lays its eggs in open wounds, which then develop into larvae and progress through instars. During this process, the larvae feed on living tissue and liquid body-substances causing lesions that are susceptible to new infestations (Batista-da-Silva et al., 2011; Costa-Júnior et al., 2019). This behavior was observed in our study on the male giant otter. Myiasis infestation caused by *C. hominivorax* was previously identified as the probable cause of death in a giant otter in the Brazilian Pantanal (Foerster et al., 2022).

The cumulative impact of these conditions on the animal's well-being extends beyond individual suffering, reducing its ability to fish and protect its habitat, and compromising its overall defensive capabilities. As expected for the social species, the disruption of social hierarchy, caused by the weakening of the dominant male in this case, can have negative effects on the group. This includes stress responses and longevity, decreased reproductive success, and loss of offspring (Tibbetts et al., 2022). In our study, the inflicted injuries disrupted the alpha male's hierarchical position within the group, further complicating the survivorship of the offspring and social dynamics. Since scent-marking plays an important role in giant otter communication, and, more specifically, in dominance hierarchy (Leuchtenberger and Mourão 2009), the decrease in scent-marking effort by the injured dominant male created new opportunities for the subordinate male to try to take the alpha's position. However, due to unspecified factors, this individual failed to secure this dominant position, allowing an earlier member ("Nick") to return to the group and assume the role of dominance.

Under certain circumstances it is expected that giant otter groups would be forced to suffer fission, disperse or die (Potts et al. 2019). In addition, G4 has established its territory in an area known for its high density of jaguars (Devlin et al., 2023), and routine conflicts with this predator are common (Leuchtenberger and Martin, 2020). Furthermore, the group faces disturbance from numerous tourist boats that visit the area daily during the dry season for jaguar safaris. The synergy of these factors, coupled with the advanced age of the dominant pair, may have influenced the reduction in the group's size in the last year and the consequent loss of defense capacity. These findings highlight the necessity for comprehensive conservation strategies that go beyond individual well-being and encompass broader ecological and social dynamics within natural habitats. Recognizing the intricate interplay between individual health, social structures, and ecological disturbances is crucial for the development and implementation of effective conservation measures for endangered species.

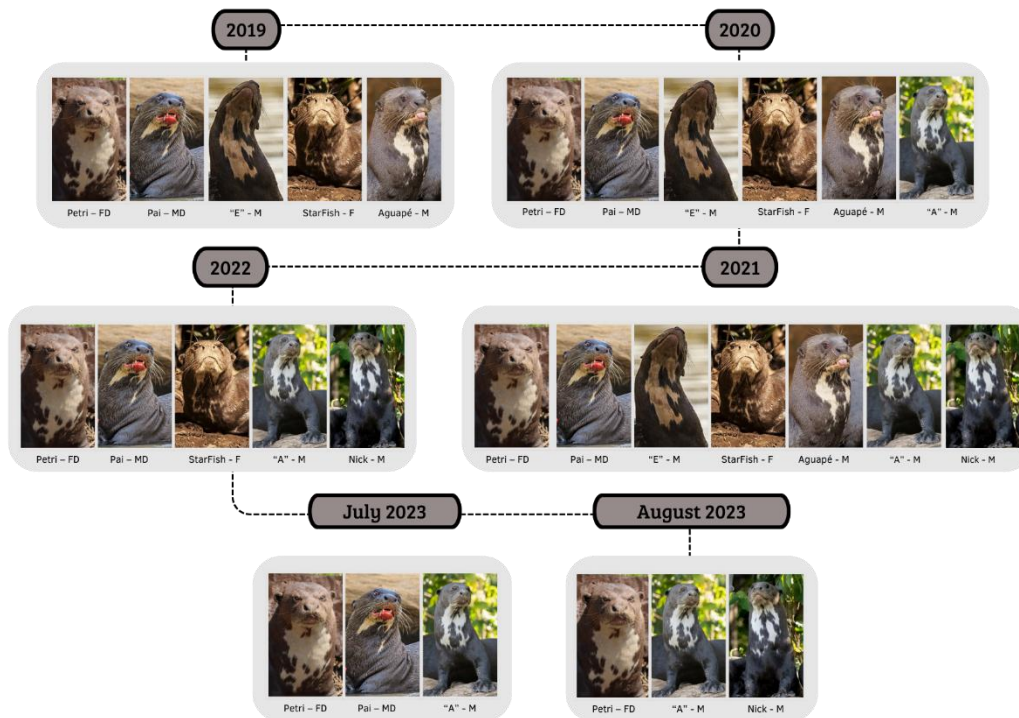
Acknowledgements - We thank Houston Zoo, Zoo Miami, IDEA Wild, and CNPq for their financial support. We are also indebted to Jaguar ID Project and Panthera Brazil Organization for their logistic support. Karen Arine Souza, Nathalie Foerstner, Helena Aimée Santos Lima and local tourism guides provided valuable information about the giant otter groups during the study. Gustavo Gaspari, Daniel

DeGranville, Cesar Moraga and Mark Thomas provided pictures used in this report.

REFERENCES

- Barros, G. P., Bricarello, P. A. (2020).** Myiasis by *Cochliomyia hominivorax* (Coquerel, 1858): a neglected zoonosis in Brazil. *Open J. Vet. Med.*, **10**(6): 80 - 91. <https://doi.org/10.4236/ojvm.2020.106007>
- Batista-da-Silva, J. A., Moya-Borja, G. E., Queiroz, M. M. (2011).** Factors of susceptibility of human myiasis caused by the New World screw-worm, *Cochliomyia hominivorax* in São Gonçalo, Rio de Janeiro, Brazil. *J. Insect Sci.*, **11**(1): 14. <https://doi.org/10.1673/031.011.0114>
- Costa-Júnior, L. M., Chaves, D. P., Brito, D. R. B., Santos, V. A. F. D., Costa-Júnior, H. N., Barros, A. T. M. (2019).** A review on the occurrence of *Cochliomyia hominivorax* (Diptera: Calliphoridae) in Brazil. *Rev. Bras. Parasitol. Vet.*, **28**: 548-562. <https://doi.org/10.1590/S1984-29612019059>
- De Dreu, C. K., Triki, Z. (2022).** Intergroup conflict: origins, dynamics and consequences across taxa. *Philos. Trans. R. Soc. B*, **377**: 20210134. <https://doi.org/10.1098/rstb.2021.0134>
- Devlin, A. L., Frair, J. L., Crawshaw Jr, P. G., Hunter, L. T., Tortato, F. R., Hoogesteijn, R., Quigley, H. B. (2023).** Drivers of large carnivore density in non-hunted, multi-use landscapes. *Conserv. Sci. Pract.*, **5**(1): e12745. <https://doi.org/10.1111/csp2.12745>
- Foerster, N., Soresini, G., Paiva, F., Silva, F. A. D., Leuchtenberger, C., Mourão, G. (2022).** First report of myiasis caused by *Cochliomyia hominivorax* in free-ranging giant otter (*Pteronura brasiliensis*). *Rev. Bras. Parasitol. Vet.*, **31**(4) : e009522. <https://doi.org/10.1590/S1984-29612022058>
- Jacobs, D., Hernandez-Camacho, C., Young, J., Gerber, L. (2008).** Determinants of Outcomes of Agonistic Interactions among Male California Sea Lions (*Zalophus californianus*). *J. Mammal.*, **89**: 1212-1217. <https://doi.org/10.1644/07-MAMM-A-171.1>
- Leuchtenberger, C., & Mourão, G. (2008).** Social organization and territoriality of giant otters (Carnivora: Mustelidae) in a seasonally flooded savanna in Brazil. *Sociobiology*, **52**(2): 257.
- Leuchtenberger, C., & Mourão, G. (2009).** Scent-marking of giant otter in the southern Pantanal, Brazil. *Ethology*, **115**(3): 210-216. <https://doi.org/10.1111/j.1439-0310.2008.01607.x>
- Leuchtenberger, C., Magnusson, W. E., Mourão, G. (2015)** Territoriality of giant otter groups in an area with seasonal flooding. *PLoS One*, **10**(5): e0126073. <https://doi.org/10.1371/journal.pone.0126073>
- Leuchtenberger, C., Martin, A. (2020).** Na terra dos grandes predadores, viver em grupo faz muita diferença. *((o))eco*. <https://oeco.org.br/analises/na-terra-dos-grandes-predadores-viver-em-grupo-faz-muita-diferenca/>
- Potts, J. R., Fagan, W. F., Mourao, G. (2019).** Deciding when to intrude on a neighbour: quantifying behavioural mechanisms for temporary territory expansion. *Theor. Ecol.*, **12**: 307-318. <https://doi.org/10.1007/s12080-018-0396-x>
- Ribas, C. & Mourão, G. (2004).** Intraspecific Agonism between Giant Otter Groups. *IUCN Otter Spec. Group Bull.* **21**(2): 89 - 93 https://www.iucnosgbull.org/Volume21/Ribas_Mourao_2004.html
- Rosas, F. C. W., Mattos, G. E. (2003).** Natural deaths of giant otters (*Pteronura brasiliensis*) in Balbina hydroelectric lake, Amazonas, Brazil. *IUCN Otter Spec. Group Bull.*, **20**(2): 62-64. https://www.iucnosgbull.org/Volume20/Weber_Rosas_de_Mattos_2003.html
- Schweizer, J. (1992).** *Ariranhas no Pantanal: Ecologia e Comportamento da Pteronura brasiliensis*. Edibran-Editora Brasil Natureza Ltda. Brazil. ISBN: 978-8585348052
- Simpson, V. R. (2000).** Intraspecific aggression and suspected infanticide in otters. *Vet. Rec.*, **146**(8): 231-232. <https://www.britishwildlife.com/back-issues/british-wildlife-116-august-2000/>
- Tibbetts, E. A., Pardo-Sanchez, J., Weise, C. (2022).** The establishment and maintenance of dominance hierarchies. *Phil. Trans. R. Soc. B*, **377**(1845): 20200450. <https://doi.org/10.1098/rstb.2020.0450>

SUPPLEMENTARY MATERIAL



Supplementary Figure 1 - Composition of the giant otter group G4, resident at the river Três Irmãos, at the Encontro das Águas State Park, in the Northern Pantanal, Brazil, between 2019 and 2023. The name of each individual is written below the individual's picture of the throat pattern, besides the sex (F - female, M - male) and dominance position (D - dominant) of the individual within the group.

RÉSUMÉ: CONFLIT INTERGROUPE ET MORTALITÉ INDUITE PAR LA MYIASE CHEZ UNE LOUTRE GÉANTE DU PANTANAL BRÉSILIEN: IMPLICATIONS POUR LA CONSERVATION DE LA POPULATION

Les rencontres agonistes, caractérisées par des confrontations et des conflits, ont été documentées chez divers taxons animaliers. Les conflits intraspécifiques sont plus fréquents dans les populations socialement structurées comme la loutre géante (*Pteronura brasiliensis*), une espèce grégaire et territoriale. Nous présentons ici l'évolution des blessures résultant d'un conflit territorial entre deux groupes de loutres géantes pendant la saison sèche dans une zone touristique perturbée du Pantanal brésilien. Les blessures d'un mâle dominant ont montré une progression défavorable d'une myiase conduisant à la mort de l'individu et des implications pour les dynamiques sociales du groupe et pour la conservation de la population.

RESUMEN: CONFLICTO ENTRE GRUPOS Y MORTALIDAD CAUSADA POR MIASIS EN UNA NUTRIA GIGANTE DEL PANTANAL BRASILEÑO: IMPLICANCIAS PARA LA CONSERVACIÓN DE LA POBLACIÓN

Los encuentros agonísticos, caracterizados por confrontaciones y conflictos, han sido documentados en diversas especies animales. Los conflictos intraespecíficos son más comunes en poblaciones estructuradas socialmente, como en la nutria gigante (*Pteronura brasiliensis*), una especie gregaria y territorial. En este estudio, presentamos la evolución de lesiones resultantes de una disputa territorial entre dos grupos de nutrias gigantes durante la estación seca en una zona turística alterada del Pantanal brasileño. Las lesiones de un macho dominante mostraron una progresión desfavorable de miasis que culminó en la muerte del individuo, con implicaciones para la dinámica social del grupo y la conservación de la población.

RESUMO: CONFLITO ENTRE GRUPOS E MORTALIDADE CAUSADA POR MIÍASE EM UMA ARIRANHA DO PANTANAL BRASILEIRO: IMPLICAÇÕES PARA A CONSERVAÇÃO POPULACIONAL

Encontros agonísticos, caracterizados por confrontos e conflitos, têm sido documentados em diversos taxa animais. Conflitos intraespecíficos são mais comuns em populações socialmente estruturadas, como no caso da ariranha (*Pteronura brasiliensis*), uma espécie gregária e territorial. Neste estudo, apresentamos a evolução das lesões resultantes de uma disputa territorial entre dois grupos de ariranhas durante a estação seca em uma área impactada pelo turismo no Pantanal brasileiro. As lesões de um macho dominante apresentaram miíase com progressão desfavorável, levando à morte do indivíduo, trazendo implicações para a dinâmica social do grupo e para a conservação da população.